

## TREATMENT AND OUTCOME OF HORSES WITH CUTANEOUS PYTHIOSIS, AND META-ANALYSIS OF SIMILAR REPORTS

Hoda Elkhenany<sup>1†\*</sup>, Shady Nabil<sup>1, 2†</sup>, Howaida Abu-Ahmed<sup>1</sup>, Hassan Mahmoud<sup>3</sup>, Ahmed Korritum<sup>1</sup>, Hoda Khalifa<sup>4</sup>

<sup>1</sup>Department of surgery, Faculty of veterinary medicine, Alexandria University, Alexandria, Egypt, <sup>2</sup>Brooke hospital for animals, Mansoura, Egypt, <sup>3</sup>Department of Information systems, Faculty of computers and informatics, Banha University, Egypt, <sup>4</sup>Department of Histology, Faculty of medicine, Alexandria University, Alexandria, Egypt  
† Equal contributor

\*Corresponding author, E-mail: hoda.atef@alexu.edu.eg

**Abstract:** Pythiosis is reported to be one of the most life-threatening infections of people and animals in tropical, subtropical and temperate areas worldwide. Infection can result from ingesting zoospores of *Pythium insidiosum* organism or from contact with water contaminated with zoospores. The ingestion of zoospores may result in enteric pythiosis, whereas cutaneous contact with zoospores/oomycete may result in cutaneous pythiosis. Here, we reported the clinical details of 10 horses with pythiosis introduced to our clinic. These horses were treated by excision of the lesion and application of an antifungal cream to the resulting wound. Also, we performed a meta-analysis of 214 horses, of 18 reports, affected with cutaneous pythiosis and analysed the influence of the horse's sex, age, lesion site, and treatment on outcome. Treatment of horses in these 18 reports varied from surgical excision, topical, regional or systemic administration of an antifungal drug, immunization, or a combination of treatments. Horses with the most successful outcome were those treated by excision of the lesion coupled with systemic or topical administration of an antifungal drug. Horses treated by immunization responded the poorest.

**Key words:** pythiosis; skin lesions; equine; surgery; *Pythium insidiosum*

---

### Introduction

Equine cutaneous pythiosis (ECP) is a granulomatous ulcerative disease caused by *Pythium insidiosum*, an aquatic fungus-like pathogen (1, 2). The cutaneous lesion caused by this pathogen has been described by some clinicians as tumor-like, rounded, large, nodular granulomatous containing necrotic tissue and "irregularly shaped yellow-tan to grey, gritty, coral-like masses commonly called kunkers or "leeches"

(1). Kunkers, or "leeches" are composed of sequestered vessels, dead eosinophils, and *Pythium* hyphae and range in size from that of a grain of rice to several centimeters wide and several centimeters long (1). Kunkers can sometimes be found in dressings, when bandages are removed (2, 3). An epidemiological survey found the incidence of mortality of horses caused by pythiosis to be 1.3% in the Brazilian Pantanal region and 2.3% in the Brazilian Cerrado region. The case fatality rate for infected horses was 23- 45.5 (4).

Because the cell wall of the oomycete of *Pythium insidiosum* is comprised primarily of cellulose and  $\beta$ -glucan, an essential component of the cell wall, researchers have suggested that administration of an inhibitor of  $\beta$ -glucan synthesis, such as caspofungin, could be an effective treatment of animals for pythiosis (5, 6). The effectiveness of caspofungin in resolving cutaneous pythiosis was tested by intraperitoneal injection in an experimentally induced pythiosis rabbit model, and results revealed reduction in the growth of the lesions, but the lesions reappeared after treatment was stopped (7).

Radical surgery, including amputation of an affected limb, is a common and effective treatment for pythiosis of human patients and animals (3, 8-10). Immunotherapy has been effective in treatment of human patients and animals for pythiosis, but results of immunotherapy vary (3, 11, 12). Combining surgical therapy with immunotherapy is more effective than is immunotherapy alone or surgery alone (4, 13).

The aims of this study were to evaluate the effectiveness of topic antifungal cream application after surgical management in 10 horses suffering from cutaneous infection of *Pythium insidiosum*. We also, performed a meta-analysis of 214 horses, in 18 reports, affected with cutaneous pythiosis to evaluate the effectiveness of different methods of treatment. This analysis also examined the influence of age, sex, pregnancy and the site of the lesion on the outcome of the infected horses.

## Materials and methods

### *Case report history and clinical signs*

Ten horses, all of which were from the Delta region of Egypt, were presented to the Brooke Hospital for Animals (BHA) between July and September 2017 for treatment for cutaneous lesions of pythiosis. These horses had one or more exudative, ulcerative, edematous, granulomatous lesions (Fig. 1A). The presumptive diagnosis of pythiosis, based on the appearance of the lesion, was confirmed by histological examination of tissue excised from the lesion, using H&E and Masson's trichrome staining. The

surface area (A) of each lesion was calculated using following equation:  $A = \pi \times r(a) \times r(b)$ , where  $r(a)$  was the half ( $\frac{1}{2}$ ) of the longitudinal diameter and  $r(b)$  was the  $\frac{1}{2}$  of transverse diameter of the lesion.

The age, sex, pregnancy status of females, site, and size of the lesion of each horse were recorded. Also recorded the date where the horse was first examined, the date of 1<sup>st</sup> surgery, date of recurrence, and the date at which the disease was considered to be resolved. Consent forms for treatment were signed by all owners.

### *Surgical excision*

The horses were sedated with xylazine HCl (1.0 mg/kg, IV; Xylaject, Adwia, Egypt) and anesthetized with propofol (2 mg/kg, IV; Deprivan, Astra Zeneca, UK). The horses were then positioned in lateral or dorsal recumbency, depending on the site of lesion.

The lesion was excised with a scalpel, after preparing the lesion and surrounding skin for surgery, then we used curette to remove the superficial layer of the skin in case of large size lesions. An antifungal cream containing terbinafine HCl (Lamisil AT 1% Cream; Novartis, Switzerland) was applied topically after surgery once daily for one week and covered with bandage. All horses were administered metronidazole (20 mg/kg, IV; Amrizole, Amriya pharm, Egypt), flunixin meglumine 0.50 mg/kg, IV; Flunix, Norbrook, U.K) and Procaine penicillin G (4 mg /100 kg, IM; Norocillin, Norbrook, U.K) for 5 days.

### *Medline database analyses*

Our meta-analysis of studies of various treatments for human patients and animals for pythiosis included 37 studies. We divided these studies into *in vitro* and *in vivo* preclinical studies (n=19) and clinical studies (n=18). Twelve preclinical studies tested the sensitivity of *P. insidiosum* to various antifungal drugs, minerals, and herbal either *in vitro alone* (n=7), *in vivo alone* (n=1) or *both in vitro and in vivo* (n=4). Seven preclinical studies were conducted to identify the molecular, proteomic, and genomic makeup of *P. insidiosum*.

We computed the significance between each treatment group, 95% confidence interval and sample odd ratio using Fisher exact test statistics using R program, ver.3.5.1

## Results

### *Surgical removal followed by application of an antifungal drug*

The 10 horses presented because of lesions caused by *P. insidiosum* were adults 3 to 11 years old (mean,  $6.5 \pm 2.6$  years), weighing 300 to 360 kg (mean,  $324 \pm 18.3$  kg). Three were male and 7 were mares. Four of the mares were pregnant. The cutaneous lesions were located on abdomen ( $n=7$ ; the lesion of one extended caudally to include the mammary glands), shoulder ( $n=1$ ), thigh ( $n=1$ ), and fetlock ( $n=1$ ). The cutaneous lesions were ranged in size from 27 to 297 mm<sup>2</sup> (mean,  $147.64 \pm 123.1$ ; Fig. 1).

The results of surgical excision and topical antifungal cream application showed that this protocol was effective in 7 out of 8 cases (87.5%). One of the horses was lost to follow-up, and another one died after the second surgery as the lesion extended to the udder and animal was emaciated with very big lesion at the time of introduction. Four of the horses recovered after excision of the lesion, but for the other four horses, signs of recurrence of the lesion appeared after surgery. These 4 horses again underwent excision of the lesion 12 to 45 days (mean 22 days) after the first surgery. The average total cure time was  $56.57 \pm 19.3$  days from the time of first surgery until the day of full recovery.

Microscopic examination of histological sections stained with H&E or Masson's Trichrome stain revealed fragments of hyphae surrounded by well-developed fibro-cellular capsule, connective tissue rich in collagen fibers, fibroblasts surrounded by eosinophils and radiating, eosinophilic material creating the histological appearance of the Splendore-Hoeppli phenomenon (Fig. 2).

### *The outcome of Medline database analysis of preclinical studies*

The antifungal drug, terbinafine HCl, was used to treat the horses for pythiosis, which is a

fungal-like disease. In one *in vitro* study of the effects of various antifungal drugs on *P. insidiosum*, miconazole was found to be the drug most effective against *P. insidiosum*, followed by ketoconazole (14). In other *in vitro* studies, some antifungal drugs were found to be ineffective against *P. insidiosum* (15). In one study, the antifungal drug caspofungin (lipopeptide) was found to have a limited fungistatic effect against *P. insidiosum* (7). In another study, the fungistatic effect of caspofungin on *P. insidiosum* was found to be similar to that resulting from immunotherapy but that treating a horse with caspofungin was more expensive than was treating a horse using immunotherapy (16). The efficacy of caspofungin against *P. insidiosum* was compared with that of other antifungal drugs in two *in vitro* studies, and in neither study was caspofungin found to be as effective as the other drugs (17, 18). Mefenoxam was found to have the highest fungal eradication (< 90%) in a study comparing the efficacy of caspofungin in resolving infection caused by *P. insidiosum* with that of itraconazole, posaconazole, voriconazole, terbinafine, and mefenoxam, Brown et al. (17). Argenta et al. (18) used caspofungin in combination with terbinafine, itraconazole, ibuprofen, or fluvastatin, and found the best combination for inhibiting growth of *P. insidiosum* to be terbinafine, itraconazole, and fluvastatin. Valente et al. (19) recently reported that plant-derived essential oils (EOs) and itraconazole worked synergistically to resolve infection caused by *P. insidiosum in vitro*. Some herbal extracts, such as propolis and garlic, which are known for their antifungal and antibacterial effect, have shown efficacy against *P. insidiosum in vitro* (20, 21).

The results of Zanette et al. (2013) study showed that an iron chelator, deferasirox, could ameliorate anemia caused by thalassemia but could not resolve lesions of pythiosis (22). They also reported that administering deferasirox in combination with immunotherapy resulted in dissemination of pythiosis to the lung. Zanette et al. (2015) treated rabbits for pythiosis with deferasirox in combination with the antifungal drug, micafungin, and reported an incidence of resolution of 88.2% (23).

Sekhon et al. (1992) reported that the polyene antibiotics, like amphotericin B, were not effective against *P. insidiosum* (14), whereas another class of antibiotics as Macrolides and tetracycline were reported to be effective against *P. insidiosum* (24). These antibiotics exert their effect on *P. insidiosum* by inhibiting protein synthesis and inhibition of amino acid transport (25). Another study examining the effect of various antibiotics with antifungal activity against *P. insidiosum* found that gentamicin, neomycin, paromomycin, and streptomycin each had an inhibitory and fungicidal effect on at least 62.5% of all *P. insidiosum* isolates from equine pythiosis; tigecycline inhibited growth of 70.8% of the isolates (26).

*In vitro* studies examining the effect of various drug on *P. insidiosum* isolated from equine lesions are summarized in Table 1.

#### *The outcome of Medline database analyses of clinical studies*

Eighteen clinical studies involving 214 horses infected with *P. insidiosum* from 7 countries, including Australia (n=5 horses), Brazil (n=106), Colombia (n=1), Costa Rica (n=39), Egypt (n=43), Thailand (n=1), and the USA (n=19), were evaluated. The youngest adult horse (above one year old) in these studies was 2 years old, and oldest was 25 years old (mean,  $11.45 \pm 6.3$ ) and foals (up to one year old) at ages ranged from 3 to 4 months with susceptibility rate only 6% in comparison to 94% for adults. The number of mares in the study group was about 2.5 times greater than the number of males. Twenty one of 59 mares (38%) for which information about pregnancy status was available were pregnant (Fig. 3).

Cutaneous lesions of pythiosis were most commonly found on the limbs (54.12%) followed by abdomen (25.88%). Less common locations of lesions included the mammary glands, the thorax, including the withers. Some horses had lesions of pythiosis in the nasal cavity or intestine.

Horses in these 18 clinical studies were treated by surgery, immunotherapy, injection of an antifungal drug into the lesion, or combination these treatments. In a report of 33 horses

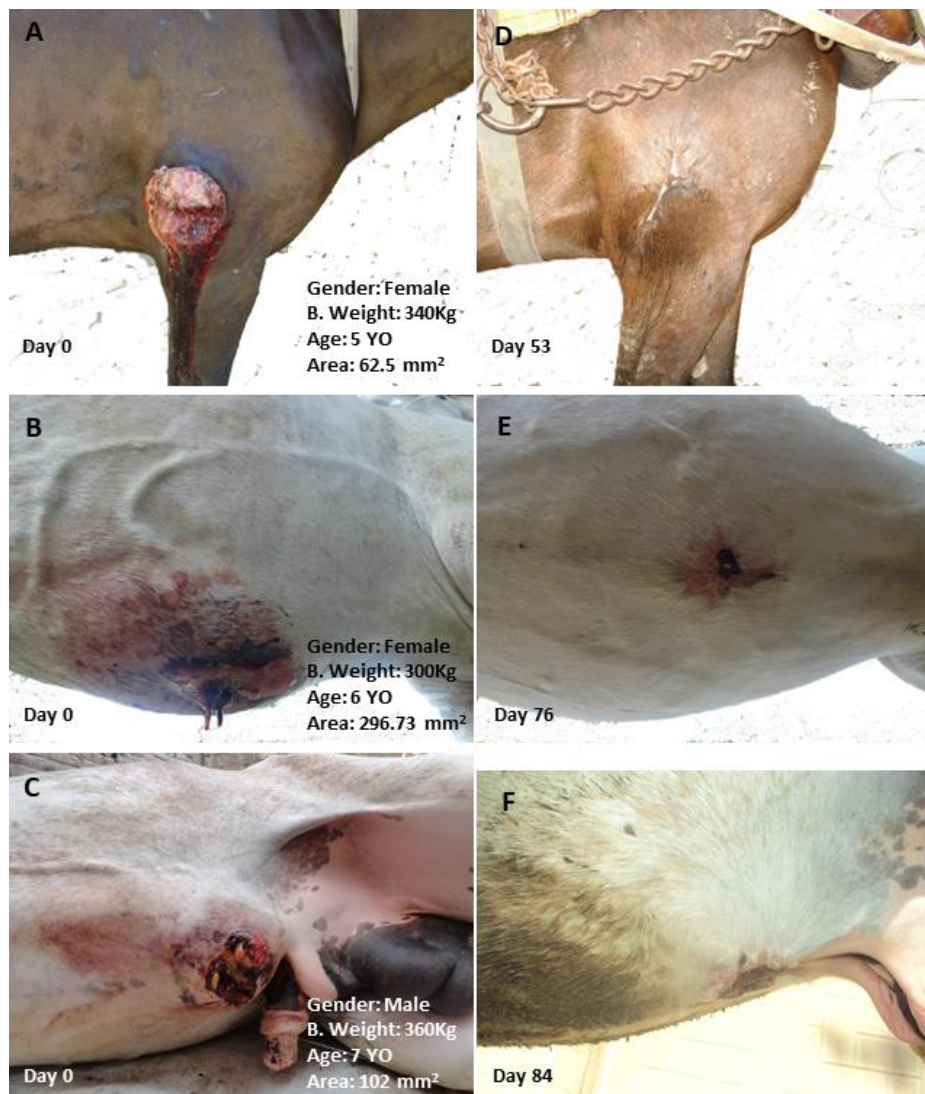
treated for pythiosis by surgery alone, 73% of horses had complete resolution of the lesions (27). Surgical excision of the lesion, coupled with oral administration sodium iodide for 2 weeks resulted in complete resolutions of lesions on the back and prepuce of a 3-monthold foal, but the time of follow-up for this foal was only 3 months (28). Statistical comparison between surgical approach alone and the empirical methods (developed by nonveterinarian where they used acids and another drugs combination) revealed a significant difference ( $P < 0.05$ , 95% Confidence interval= 1.09-23.59 and odd ratio= 4.75) between treatments (Figure 3D). Eighty percent of horses in our study had complete resolution of cutaneous pythiosis after they were treated by surgical excision of the lesion and by topical application of an antifungal cream to the resulting wound. In another study of horses affected with cutaneous pythiosis reported that 80% of horses had complete resolution of lesion after local injection with amphotericin B (8). When the antifungal drug, amphotericin B, administered by intravenous regional limb infusion (IV-RLP) after surgical excision to resolve lesions of pythiosis located on the distal portion of the limb, 92% of horses had complete resolution of infection (29). When amphotericin B administered in combination with 10% DMSO, 100% of horses had complete resolution of infection (30). The complete infection resolution was significantly higher among horses that received surgery and I V-RLP with amphotericin B than among horses that received surgery alone ( $P < 0.0067$ , 95% confidence interval=1.39-24.06 and odd ratio=5.14). The complete resolution of infection was significantly higher among horses that received IV-RLP with amphotericin B, with or without DMSO, than among horses that were treated empirically ( $P < 0.00001$ , 95% confidence interval= 4.35- 154.2 and odd ratio=22.47) (Fig. 3). Immunotherapy alone was used to treat 36 horses for pythiosis in 3 studies (4, 12, 13).

Immunotherapy combined with surgery was used to treat 24 horses for pythiosis in 4 studies (3, 4, 11, 31). There was no significant difference in incident of resolution between those

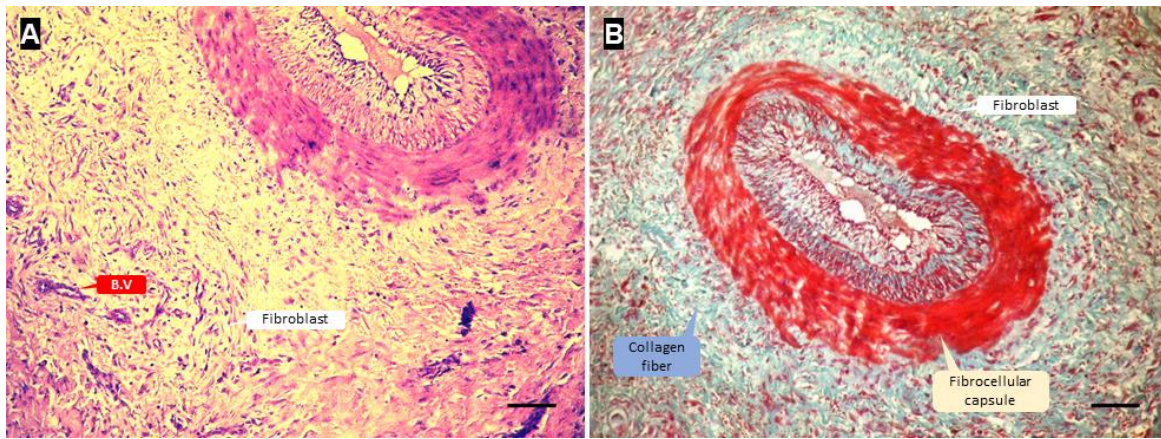
horses that were treated with immunotherapy alone and those horses treated with surgery in addition to immunotherapy ( $P = 1$ , 95% confidence interval=0.246-3.80, and odd ratio=1). The outcome of horses in the group that received only immunotherapy was significantly better than the outcome of 15 horses treated empirically ( $P < 0.001$ , 95% confidence interval=1.78-42.87 and odd ratio=7.84). The outcome of horses were treated with a combination of immunotherapy and surgery was also significantly higher than the outcome of horses treated empirically ( $P < 0.01$ , 95% confidence interval=0.00-116.7 and odd ratio=0) (Fig. 3B).

One report described using photoablation with a neodymium: *yttrium-aluminum garnet* laser after excising the lesion of two horses to induce thermal necrosis of infected tissue that surgeons failed to remove at time of surgery (32). The authors reported that the lesions had not recurred after one year.

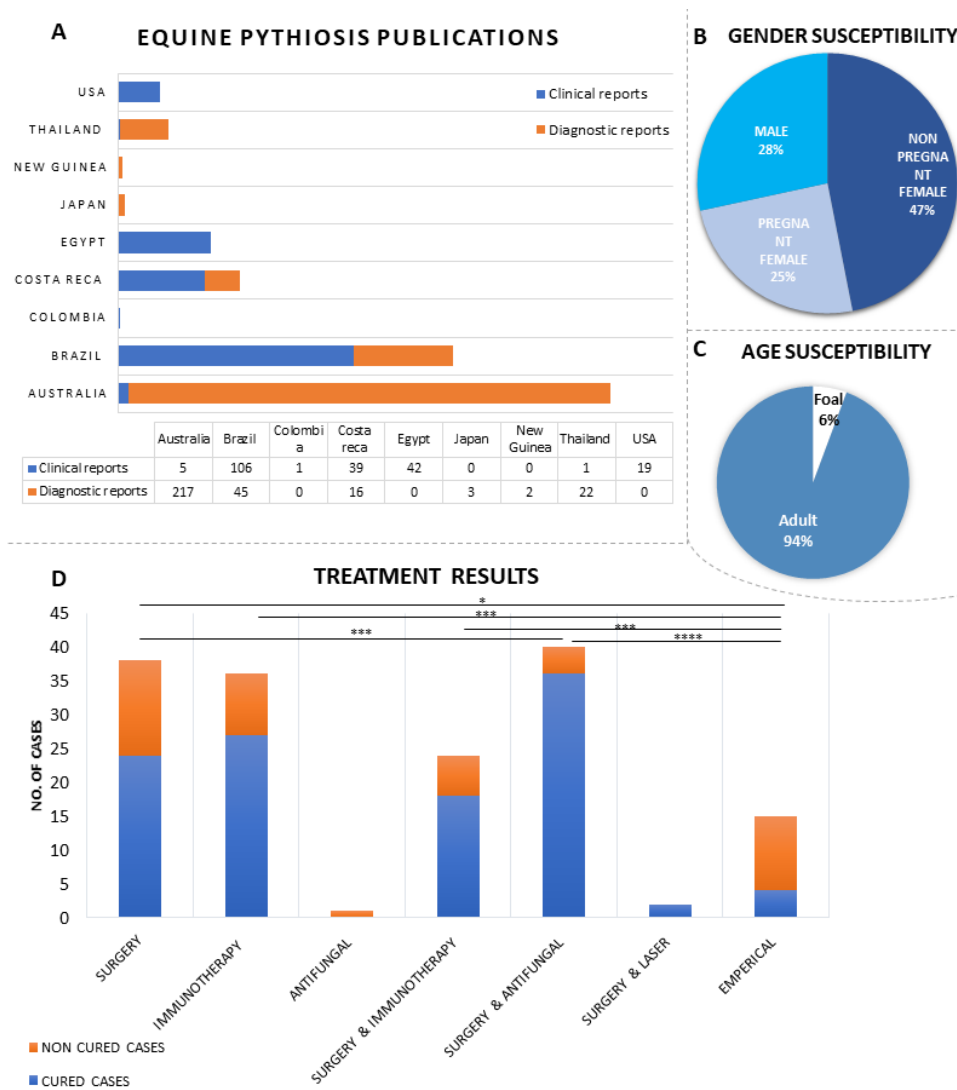
The results of all the published studies of horses undergoing treatment for pythiosis, including the number of horses in each study, age, sex, methods of treatment, and the incidence of resolution are summarized in Table 2.



**Figure 1:** Representative clinical cases diagnosed as cutaneous pythiosis, before surgical intervention (A, B and C) and after complete recovery (D, E and F). Each case has a brief information about the case as the gender, weight, age and the surface area of the lesion on the lower left corner of the image (A, B and C) also the day of the recovery at the lower right corner in (D, E and F) images



**Figure 2:** Representative histological section of skin lesion stained with H&E (A) and Trichome Stain (B) showing the characteristic Splendore-Hoeppli like reaction. Scale bar = 500 μm



**Figure 3:** MEDLINE database analysis of clinical cases. (A) Publications around the world, bars represent no. of animals in all studies published/country (B) Gender susceptibility, (C) Age susceptibility and (D) MEDLINE database analysis comparing between different treatment approaches that have been used to treat equine pythiosis, \*P<0.05, \*\*\*P<0.001, \*\*\*\*P<0.000001

**Table 1:** Summary of published preclinical studies *in vitro* and *in vivo* using different antifungal drugs, minerals and herbals to eradicate *P. insidiosum*

Drugs	Drug under investigation	In vitro/ In vivo	Animal M/F /Age	Results	RE F
Antifungal drugs	Amphotericin B, hamycin, 5-fluorocytosine, fluconazole, itraconazole, ketoconazole and miconazole	In vitro	-	<i>P. insidiosum</i> were sensitive to fluconazole, ketoconazole, and miconazole and miconazole was the strongest one.	(14)
	Terbinafine, itraconazole, caspofungin, ibuprofen and Fluvastatin	In vitro and In vivo	Rabbit (M/3m)	Terbinafine, itraconazole and Fluvas-tatin combination resulted in the lowest hyphae number.	(18)
	Caspofungin	In vitro and In vivo	Rabbit (M&F/3 m)	The results showed that caspofungin has limited fungistatic activity against <i>P. insidiosum</i> .	(7)
	Immunotherapy and caspofungin	In vivo	Rabbit (M&F/3 m)	No significant difference between both treatments but the cost of the immunotherapy is lower than caspofungin.	(16)
	Itraconazole, posaconazole, voriconazole, terbinafine, caspofungin, and mefenoxam.	In Virto	-	Mefenoxam had a profound effect on <i>P. insidiosum</i> at concentration 1 µg/ml with >90% inhibition rate	(17)
Iron chelator	Immunotherapy, Iron chelator deferasirox and combination of both	In vitro and In vivo	Rabbit (F/3m)	Deferasirox alone did not result in any significant enhancement for the lesion from the control. However, it could ameliorate the anemia. The combination between the immunotherapy and iron were the worse than the immunotherapy alone.	(22)
	Micafungin with or without deferasirox	In vitro and In vivo	Rabbit (F/3m)	Micafungin alone is not effective against <i>P. insidiosum</i> but effective when combined with deferasirox cure rate 88.2% however, disease dissemination in the lung were reported.	(23)
Herbal extracts	Terbinafine or itraconazole with <i>Melaleuca alternifolia</i> , <i>Mentha piperita</i> and <i>Origanum vulgare</i> essential oils (EOs)	In vitro	-	The antimicrobial combinations using EOs with terbinafine or itraconazole can be an attractive therapeutic option for controlling <i>P. insidiosum</i> infections.	(19)
	Propolis and geopropolis in a final volume of 1.0 mL	In vitro	-	Propolis was more efficient than geopropolis in inhibiting <i>P. insidiosum</i> .	(20)
	Garlic extract	In vitro	-	garlic extract has strong inhibitory activity toward <i>P. insidiosum</i>	(21)
Antibiotics	Macrolides and tetracycline antibiotics	In Virto	-	Macrolides and tetracycline antibiotics had an effective inhibitory effect for the <i>P. insidiosum</i>	(24)
	Aminoglycoside antibiotics and tigecycline	In Virto	-	Tigecycline showed the lowest MIC (0.25 to 2 mg/liter) and MFC (1 to 8 mg/liter) range values. The in vitro susceptibility observed to tigecycline makes this drug a good option for management of pythiosis	(26)

**Table 2:** Summary of published studies on clinical studies including the number of animals under investigation in each study, age, gender, methods of treatment and the recovery rate

REF	Place of study	Site of infection	Cases No	Gender	Age	Treatment approach	Result
(4)	Brazil	Cutaneous	76	-	75 Adult	-Immunotherapy -Surgery and Immunotherapy -Empirical	Immunotherapy showed 79.4% efficacy however, combination of immunotherapy and surgery resulted in the highest recovery rate 84.6%
(30)	Brazil	Distal limb	15	7 F 8 M	4M-15Y	IRP of amphotericin B in a 10 % DMSO	Complete resolutions of the lesion between 6 to 9 weeks after a single treatment
(29)	Brazil	Distal limb	12	8 F 4 M	4M-10Y	Intravenous regional perfusion (IRP) of amphotericin B	Complete lesion resolution in 92% of case after 35 to 60 days
(12)	Brazil	Cutaneous	1	M	-	Immunotherapy	Lesion disappeared after 5 doses immunotherapy and the recurrence was detected 2 years later in the abdomen
This study	Egypt	Cutaneous	10	7 F 3 M	3-11Y	Surgical excision followed by local anti-fungal injection	Most of them required a 2 <sup>nd</sup> surgical intervention 80% Cure rate
(27)	Egypt	Cutaneous	33	29 F 4 M	3-9Y	Surgical excision	Surgical excision resulted in 73% cure rate
(8)	USA	Cutaneous	10	-	-	Surgery followed by Amphotericin B IV and local	80% Cure rate
(31)	USA	Cutaneous	3	F	1.5Y-10Y	2 cases surgical excision 1 case surgery and immunotherapy	The treatment failed and all of them were died. mammary part, nostrils, both limbs and maxillary region, necropsy showed granulomatous lesion in lung and liver
(39)	USA	Cutaneous, extend to bone	1	F	9Y	-Antimicrobial and sodium iodide, IV injection -Surgical excision and regional antifungal injection	-Treatment with antimicrobials for 12 days, debridement, and i.v. administration of sodium iodide resulted in disease progression. - Surgical excision and regional antifungal injection were the most effective.
(32)	USA	Cutaneous	2	-	-	Surgery followed by Photoablation	Complete cure and no recurrence detected for up to 1 year
(13)	USA	Limb	1	F	18Y	Immunization	The case did not respond to vaccine and euthanized after 5 weeks
(28)	USA	Cutaneous	1	M	3M	Surgery followed by sodium iodide oral	Complete healing
(41)	USA	Enteric pythiosis	1	M	2Y	Surgery	No report about the recovery
(3)	Costa reca	Cutaneous	39	-	-	Surgery and Immunotherapy	Only five horses were treated. 3 of them respond to the treatment however the other 2 cases did not respond as they were chronic pythiosis
(11)	Australia	Cutaneous	5	-	-	Surgery, antifungal, Immunization	Surgery and antifungal were ineffective, Vaccine resulted in 1 completely cured, 3 developed osteitis and one died before completing vaccine course
(42)	Colombia	Enteric pythiosis	1	F	8Y	-	-
(43)	Thailand	Nasal cavity	1	F	4Y	Surgical removal, local injection of mix of Ampho. B, DMSO and ringer lactate then topical application of antifungal cream	-Complete healing and recovery after 3 Weeks

## Discussion

Horses that develop pythiosis reside most commonly in a tropical, subtropical, or temperate region (33), and consequently, horses in most of the published reports of pythiosis were located in Australia, Brazil, Colombia, Costa Rica, Egypt, Thailand, and southern states in USA.

The presence of kunkers within granulation tissue is a grossly observable characteristic of cutaneous lesions of pythiosis, and the Splendore-Hoeppli phenomenon, an immunological reaction surrounding the causative agent, is a histologically observable characteristic.

Infection caused by *P. insidiosum* stimulate T-helper 2 (Th2) cells in the infected host, which causes eosinophils and mast cells to surround the hyphae of *P. insidiosum*. Degranulation of these cells leads to a Splendore-Hoeppli reaction. This reaction in horses is so intensive that kunkers develop (34).

Drugs interfering with the biosynthesis of ergosterol, like the azoles (itraconazole, ketoconazole, miconazole, and fluconazole), terbinafine, and amphotericin B, change the permeability of the cell membrane, causing lysis fungal cell. Because the cell membrane of the *P. insidiosum* is composed mainly of cellulose and  $\beta$ -glucan, thus the above mentioned drugs predictable to have little effect on *P. insidiosum*. Nevertheless, people and horses infected with *P. insidiosum* have been treated successfully with drugs that interfere with the biosynthesis of ergosterol (35-37).

*P. insidiosum* has been reported to be sensitive to inhibitors of biosynthesis of ergosterol and  $\beta$ -glucan (6, 7, 17, 18, 37, 38). The efficacy of various antifungal drugs in the treatment of horses for pythiosis varied widely among the studies and depended on whether ergosterol was present in the cytoplasmic membrane of the oomycete (14, 34).

Not all antifungal drugs used to treat horses for pythiosis in these studies were effective against *P. insidiosum*. Caspofungin, for example, was found to be ineffective against *P. insidiosum*. Mefenoxam or a combination of antifungal drugs, such as terbinafine, itraconazole and fluvastatin, however, may be effective in

inhibiting fungal growth and may provide a high incidence of resolution of infection. Data suggest that injecting the antifungal drug locally into the lesion or administering it by intravenous regional limb perfusion increases the likelihood of resolving infection (8, 29, 39). Adjuvants, such as essential oils, iron chelators and DMSO have been combined with antifungal drugs to increase the efficacy of the antifungal drugs, in preclinical and clinical studies (19, 23, 30).

The *in vivo* effect of a drug may be different than that expected based on *in vitro* testing of that drug. For instance, Sekhon et al. (14) showed that amphotericin was not effective against *P. insidiosum*, but Doria et al. (2012) reported that 92% of horses experienced resolution of lesions caused by *P. insidiosum* on one or more limbs when amphotericin B was administered by IV-RLP (29).

The herbal extracts, propolis and garlic, appeared to be effective against *P. insidiosum in vitro*, though we can find no reports describing the use of these herbs clinically (20, 21).

Adult horses have been reported to be 8 times more susceptible than foals to infection caused by *P. insidiosum* (4), but meta-analysis of the studies we report shows that adults appear to be 16 times more likely than foals to become infected with *P. insidiosum*. Meta-analysis of susceptibility according to gender showed that the females are more likely than males to be presented because of infection caused by *P. insidiosum* (72% vrs 28%). Mendoza and Alfaro (1986), on the other hand, reported that pythiosis had no sex or age predilection (3).

Regarding the treatment, based on the meta-analysis, we found that the best approach to be surgical excision coupled with application of an antifungal drug topically or, if the lesion was located on the distal portion of the limb, by IV-RLP. There was no significant difference between the efficacy of immunotherapy used alone and the efficacy of immunotherapy used in conjunction with surgery. This can be explained by the short follow-up periods after the immunotherapy. Longer follow-up revealed that immunotherapy alone resulted in recurrence after 2 years as reported by Santos et al.

(12). This may be explained by the progressive decrease in IgG antibody titers after administration of immunotherapy, which could result in titers too low to protect the host after one year (40).

## Conclusion

The excision of a cutaneous lesions of pythiosis was proved to be an effective treatment of affected horses, especially when combined with local or regional administration of an antifungal drug. Also, combining DMSO with the antifungal has revealed a higher cure rate. Because propolis was shown to be effective against *P. insidiosum* in vitro, we suggest testing its efficacy clinically. Including propolis in the treatment protocol is expected to be more efficient as it has antibacterial and antifungal in addition to its high regenerative capacity. Also, photoblation was suggested as effective treatment for horses with cutaneous pythiosis, but more studies are needed to prove its efficacy.

## Conflict of interest

The authors declare that they have no conflict of interest.

## Limitations

Some studies did not include enough data about the sex, age, and pregnancy status, so our analysis was based only on the studies that included that data.

## Acknowledgements

The authors would like to express very great appreciation to Dr. James Schumacher (Professor of large animal clinical science, University of Tennessee) for editing this manuscript.

## References

1. Chaffin, M.K., S. James, and W.C. McMullan, Cutaneous pythiosis in the horse. *Veterinary Clinics of North America: Equine Practice*, 1995. 11(1): p. 91–103.
2. Mendoza, L., L. Ajello, and M. McGinnis, Infections caused by the oomycetous pathogen *Pythium insidiosum*. *Infecciones causadas por el patógeno oomiceto *Pythium insidiosum**. *Journal de Mycologie Medicale.*, 1996. 6(4): p. 151–64.

3. Mendoza, L. and A.A. Alfaro, Equine pythiosis in Costa Rica: report of 39 cases. *Mycopathologia*, 1986. 94(2): p. 123–29.
4. dos Santos, C.E.P., et al., Epidemiological Survey of Equine Pythiosis in the Brazilian Pantanal and Nearby Areas: Results of 76 Cases. *Journal of Equine Veterinary Science*, 2014. 34(2): p. 270–4.
5. Hendrix, J.W., Sterol induction of reproduction and stimulation of growth of *Pythium* and *Phytophthora*. *Science*, 1964. 144(3621): p.1028–9.
6. Cavalheiro, A.S., et al., In vitro activity of terbinafine associated to amphotericin B, fluvas-tatin, rifampicin, metronidazole and ibuprofen against *Pythium insidiosum*. *Veterinary microbiology*, 2009. 137(3-4): p. 408–11.
7. Pereira, D.I.B., et al., Caspofungin in vitro and in vivo activity against Brazilian *Pythium insidiosum* strains isolated from animals. *Journal of Antimicrobial Chemotherapy*, 2007. 60(5): p. 1168–71.
8. McMullan, W.C., et al., Amphotericin B for the treatment of localized subcutaneous phycomycosis in the horse. *J Am Vet Med Assoc*, 1977. 170(11): p. 1293–8.
9. Chitasombat, M.N., et al., Clinicopathological features and outcomes of pythiosis. *Int J Infect Dis*, 2018. 71: p. 33–41.
10. Reanpang, T., et al., Vascular Pythiosis of the Lower Extremity in Northern Thailand: Ten Years' Experience. *Int J Low Extrem Wounds*, 2015. 14(3): p. 245–50.
11. Miller, R.I., et al., Complications associated with immunotherapy of equine phycomycosis. *J Am Vet Med Assoc*, 1983. 182(11): p. 1227–9.
12. Santos, C.E., et al., Does immunotherapy protect equines from reinfection by the oomycete *Pythium insidiosum*? *Clin Vaccine Immunol*, 2011. 18(8): p. 1397–9.
13. White, S.D., et al., Cutaneous pythiosis in a nontravelled California horse. *Vet Dermatol*, 2008. 19(6): p. 391–4.
14. Sekhon, A.S., A.A. Padhye, and A.K. Garg, In vitro sensitivity of *Penicillium marneffe* and *Pythium insidiosum* to various antifungal agents. *European Journal of Epidemiology*, 1992. 8(3): p. 427–32.
15. Madoui, M.A., et al., Sterol metabolism in the oomycete *Aphanomyces euteiches*, a legume root pathogen. *New Phytologist*, 2009. 183(2): p. 291–300.
16. Pereira, D.I.B., et al., Comparison between immunotherapy and caspofungin as agents to treat experimental pythiosis in rabbits. *Journal de Mycologie Médicale*, 2008. 18(3): p. 129–33.

17. Brown, T.A., A.M. Grooters, and G.L. Hosgood, In vitro susceptibility of *Pythium insidiosum* and a *Lagenidium* sp to itraconazole, posaconazole, voriconazole, terbinafine, caspofungin, and mefenoxam. *American journal of veterinary research*, 2008. 69(11): p. 1463–8.
18. Argenta, J.S., et al., In vitro and in vivo susceptibility of two-drug and three-drug combinations of terbinafine, itraconazole, caspofungin, ibuprofen and fluvastatin against *Pythium insidiosum*. *Veterinary Microbiology*, 2012. 157(1): p. 137–42.
19. Valente, J.S., et al., In vitro activity of antifungals in combination with essential oils against the oomycete *Pythium insidiosum*. *J Appl Microbiol*, 2016. 121(4): p. 998–1003.
20. Araujo, M.J., S.M. Bosco, and J.M. Sforcin, *Pythium insidiosum*: inhibitory effects of propolis and geopropolis on hyphal growth. *Braz J Microbiol*, 2016. 47(4): p. 863–9.
21. Zanette, R., et al., In vitro susceptibility of *Pythium insidiosum* to garlic extract. *African Journal of Microbiology Research*, 2011. 5(29): p. 5316–8.
22. Zanette, R.A., et al., Iron chelation therapy as a treatment for *Pythium insidiosum* in an animal model. *J Antimicrob Chemother*, 2013. 68(5): p. 1144–7.
23. Zanette, R.A., et al., Micafungin alone and in combination therapy with deferasirox against *Pythium insidiosum*. *J Mycol Med*, 2015. 25(1): p. 91–4.
24. Loreto, E.S., et al., In vitro susceptibility of *Pythium insidiosum* to macrolides and tetracycline antibiotics. *Antimicrob Agents Chemother*, 2011. 55(7): p. 3588–90.
25. Rawn, C.D. and J.L. Van Etten, Mechanism of antibacterial antibiotic sensitivity in *Pythium ultimum*. *Microbiology*, 1978. 108(1): p. 133–9.
26. Mahl, D.L., et al., In vitro susceptibility of *Pythium insidiosum* isolates to aminoglycoside antibiotics and tigecycline. *Antimicrob Agents Chemother*, 2012. 56(7): p. 4021–3.
27. Mosbah, E., et al., Diagnosis and Surgical Management of Pythiosis in Draft Horses: Report of 33 Cases in Egypt. *Journal of Equine Veterinary Science*, 2012. 32(3): p. 164–9.
28. Chaffin, M.K., J. Schumacher, and N. Hooper, Multicentric cutaneous pythiosis in a foal. *J Am Vet Med Assoc*, 1992. 201(2): p. 310–2.
29. Doria, R.G., et al., Treatment of pythiosis in equine limbs using intravenous regional perfusion of amphotericin B. *Vet Surg*, 2012. 41(6): p. 759–65.
30. Doria, R.G., et al., Evaluation of intravenous regional perfusion with amphotericin B and dimethylsulfoxide to treat horses for pythiosis of a limb. *BMC Vet Res*, 2015. 11: p. 152.
31. Reis, J.L., et al., Disseminated pythiosis in three horses. *Veterinary Microbiology*, 2003. 96(3): p. 289–5.
32. Sedrish, S., et al., Adjunctive use of a neodymium: yttrium-aluminum garnet laser for treatment of pythiosis granulomas in two horses. *Journal of the American Veterinary Medical Association*, 1997. 211(4): p. 464–5.
33. Pier, A., et al., Prominent animal mycoses from various regions of the world. *Sabouraudia*, 2000. 38(Supplement\_1): p. 47–58.
34. Mendoza, L. and J.C. Newton, Immunology and immunotherapy of the infections caused by *Pythium insidiosum*. *Medical Mycology*, 2005. 43(6): p. 477–86.
35. Triscott, J.A., D. Weedon, and E. Cabana, Human subcutaneous pythiosis. *Journal of Cutaneous Pathology*, 1993. 20(3): p. 267–71.
36. Shenep, J.L., et al., Successful medical therapy for deeply invasive facial infection due to *Pythium insidiosum* in a child. *Clinical infectious diseases*, 1998. 27(6): p. 1388–93.
37. Grooters, A.M., Pythiosis, lagenidiosis, and zygomycosis in small animals. *Veterinary Clinics: Small Animal Practice*, 2003. 33(4): p. 695–720.
38. Cavalheiro, A.S., et al., In vitro activity of terbinafine combined with caspofungin and azoles against *Pythium insidiosum*. *Antimicrobial agents and chemotherapy*, 2009. 53(5): p. 2136–8.
39. Worster, A.A., et al., Pythiosis with bone lesions in a pregnant mare. *Journal of the American Veterinary Medical Association*, 2000. 216(11): p. 1795–8.
40. Gaastra, W., et al., *Pythium insidiosum*: an overview. *Vet Microbiol*, 2010. 146(1-2): p. 1–16.
41. Allison, N. and J.P. Gillis, Enteric pythiosis in a horse. *J Am Vet Med Assoc*, 1990. 196(3): p. 462–4.
42. Purcell, K.L., et al., Jejunal obstruction caused by a *Pythium insidiosum* granuloma in a mare. *J Am Vet Med Assoc*, 1994. 205(2): p. 337–9.
43. Tonpitak, W., et al., First confirmed case of nasal pythiosis in a horse in Thailand. *JMM Case Rep*, 2018. 5(1): p. e005136.