

DETECTION OF DNA ALTERATIONS IN MUSCOVY DUCKS (*CAIRINA MOSCHATA*) NATURALLY INFECTED WITH HIGHLY PATHOGENIC AVIAN INFLUENZA VIRUS SUBTYPE H5N1

Iman E. El-Araby¹, Reham M. ElBakrey², Haytham Ali^{3,5}, Mahmoud H.A. Mohamed², Shima M.G. Mansour⁴, Amal A.M. Eid^{2*}

¹Department of Animal Wealth Development, ²Department of Avian and Rabbit Medicine, ³Department of Pathology, ⁴Department of Virology, Faculty of Veterinary Medicine, Zagazig University, Zagazig, Egypt, ⁵Department of Animal and Veterinary Sciences, College of Agricultural and Marine Sciences, Sultan Qaboos University, Muscat, Sultanate of Oman

*Corresponding author, E-mail: amalaeidvet@gmail.com

Abstract: Highly pathogenic avian influenza virus (HPAIV) subtype H5N1 is circulating in Egypt since 2006, with escalating apprehension about its possibility to become more transmissible amongst humans. In this study, three serial outbreaks of HPAIV H5N1 in domestic Muscovy ducks in Sharkia Governorate, Egypt were investigated. Nervous signs with 62% mortality were observed in Muscovy ducklings. Gross examination revealed severely congested meningeal vessels, hemorrhages on the duodenum, pancreas, and coronary fat. Perivascular lymphocytic cuffing, gliosis and vacuolation of the neuropil were observed in the brain microscopically. Viral antigens were identified in the neurons and the glial cells of the cerebral cortex, submucosal Meissner's plexus neurons of the intestine and the hepatic Kupffer cells by immunohistochemistry. The HPAIV subtype H5N1 was isolated from different duck tissues in 66.7% of examined duck samples. Using RAPD-PCR fingerprinting, there were different patterns in the DNA of Muscovy ducks naturally infected with AIV (24, 48 and 72 hours post appearance of clinical signs) compared to uninfected birds. Differences in RAPD-PCR profiles between infected and uninfected ducks, and genomic instability percent ($37.7\% \pm 1.76$) pointed to the incidence of DNA alterations induced at 24 hours following the appearance of clinical signs. Further *in vivo* and *in vitro* experiments need to be done to determine the relative importance of these findings.

Key words: GTS %; H5N1; RAPD-PCR; Egypt

Introduction

Influenza A viruses belonging to family Orthomyxoviridae, are enveloped, negative sense, segmented single-stranded RNA viruses. They are categorized into 18 haemagglutinin and 11 neuraminidase subtypes (1). According to the pathogenicity of avian influenza viruses

(AIVs) in chickens, they are classified into highly pathogenic and low pathogenic viruses (2). Since 2006, highly pathogenic avian influenza virus (HPAIV) subtype H5N1 is circulating in Egypt. Uncontrolled outbreaks in both vaccinated and non-vaccinated flocks as a result of the continuous mutation (3) and evolution of new viruses has been encountered.

Consequently, massive financial losses in the poultry industry, and proved human cases were reported (4). Beside, the uniqueness of the influenza virus replication that is unusual for an RNA virus is its dependence on nuclear functions as well as interaction with host cell, partially due to the contribution of a variety of cellular activities, resources and biosynthesis as well as transport machinery during the course of infection (5).

Ducks are considered as a crucial reservoir for AIV (6). In Egypt, ducks are nearly all reared in the backyard sector. Earlier, greenish diarrhea, nervous signs, and/or sudden death were recorded among infected ducks. The segmented RNA genomes of AIVs are unstable in duck inhabitants, being constantly rearranged by reassortment (7). Several molecular surveillances revealed close relatedness of HPAI viruses from backyard ducks and humans (8-10). Additionally, the AIV may be enduring genetic diversity, evolving into multiple genotypes. Viral and host factors are equally sharing in continuous evolution of influenza viruses (3). Acute fatal disease caused by systemic replication of influenza virus is commonly recorded with HPAIV infections (11).

Random Amplified Polymorphic DNA (RAPD) is considered as a reliable molecular technique that has benefited from the advent of the PCR (12) and used for detection of DNA alterations. The ordinary use of RAPD involves detection of differences between strains and individuals in organisms (13,14). This study is reporting the application of RAPD on DNA of brain tissues under the impact of natural HPAIV infections among Muscovy ducks in Sharkia Governorate, Egypt. We attempted to use this approach to assess differences between genome of AIV infected ducks and uninfected ones to appraise the effect of AIV infection on DNA alteration.

Material and methods

Viruses

The H5N1 HPAIV was isolated from Muscovy duck tissues during three outbreaks in Sharkia Governorate, Egypt during 2014-2016.

Samples were collected for virus isolation and histopathological examination. The virus isolation from prepared tissue samples was done in nine to eleven day-old embryonated chicken eggs (ECEs) via the allantoic route following OIE directions (15). Allantoic fluids were harvested and examined with rapid HA assay using 10% chicken RBCs. At least three blind passages were carried out for the sample to be negative. The viruses were identified using reverse transcriptase-polymerase chain reaction (RT-PCR).

RNA extraction and RT-PCR

The RNA was extracted from HA-positive allantoic fluids, using Gene JET™ RNA purification kit (Thermo scientific, UK). The RT-PCR was carried out using Verso™ One Step RT-PCR Kit (Thermo scientific, UK) and specific primers for the H5 gene (16) and N1 gene (17). Duck hepatitis virus type 1 (DHV-1) infection was tested by RT-PCR with 3D gene specific primers (18).

Pathology and Immunohistochemistry

The birds were necropsied and different tissue samples were collected and fixed in 10% formalin. Samples were processed in a series of alcohol concentrations, cleared in xylene, and embedded in paraffin. Five micron sections were stained with hematoxylin and eosin (H&E). For immunohistochemistry (IHC) staining, consecutive sections were mounted on positively charged microscope slides and stained using a mouse-derived monoclonal anti-influenza A nucleoprotein (NP) clone A1 and A3 (NR4282, BEI Resources; Manassas, VA) as a primary antibody at 1:200 dilution. Specific bindings were seen using the Dako EnVision system (DakoCytomation Inc. Carpinteria, CA, USA) and hematoxylin as a counter stain. Brown color appeared as a positive signal at the site of binding (19).

DNA extraction and RAPD-PCR

Three Muscovy duckling flocks were investigated using RAPD-PCR to assess the effect of AIV infection on cellular DNA. Brain tissues were collected from ducks infected with AIV at 24h, 48h and 72h following appearance

of clinical signs. Samples from uninfected Muscovy ducks were collected as well. The infection was confirmed by virus isolation, RT-PCR, and IHC in brain tissues. The DNA was extracted from AIV infected (n=27) and uninfected (n=9) Muscovy duck brains using Genomic DNA purification kit (Thermo scientific, UK). Eight random primers; OPA-08-14: GTG ACG TAG G; OPA-10-14: GTG ATC GCA G; OPA-20-14: GTT GCG ATC C; OPB-01-14: GTT TCG CTC C; OPB-11-14: GTA GAC CCG T; OPB-15-14: GGA GGG TGT T; OPC-01-14: TTC GAG CCA G; OPE-19-14: GTT GCG ATC C (Operon Technologies Inc, USA) were used for RAPD-PCR. The technique was carried out in 0.2 ml PCR tubes using DreamTaq Green PCR Master Mix (Thermo scientific, UK). The cycling conditions were as follows; 5 min at 94°C, 1 min at 94°C, 1 min at 32°C, and 2 min at 72°C, then 7 min at 72°C for final extension at the end of 40 cycles. The amplified products were run on 1.5% agarose gels. Scoring process was

done; number 1 was given to the samples that produced the band and 0 to the samples that failed to produce it. Every separate DNA effect seen in the RAPD-PCR profiles (absence of bands and presence of new bands in comparison with uninfected profiles) was considered in order to assess any DNA alteration. The genomic template stability percent (GTS %) was calculated for each infected duck with the chosen primer as follows: $GTS (\%) = (1 - a/n) \times 100$ where "a" is the number of RAPD polymorphic profiles detected in each infected duck and "n" is the number of total bands in uninfected ducks (20).

Statistical analysis

The data were analyzed with one-way ANOVA and comparison of means was done using Duncan's multiple range tests and expressed as mean \pm standard error.

Results

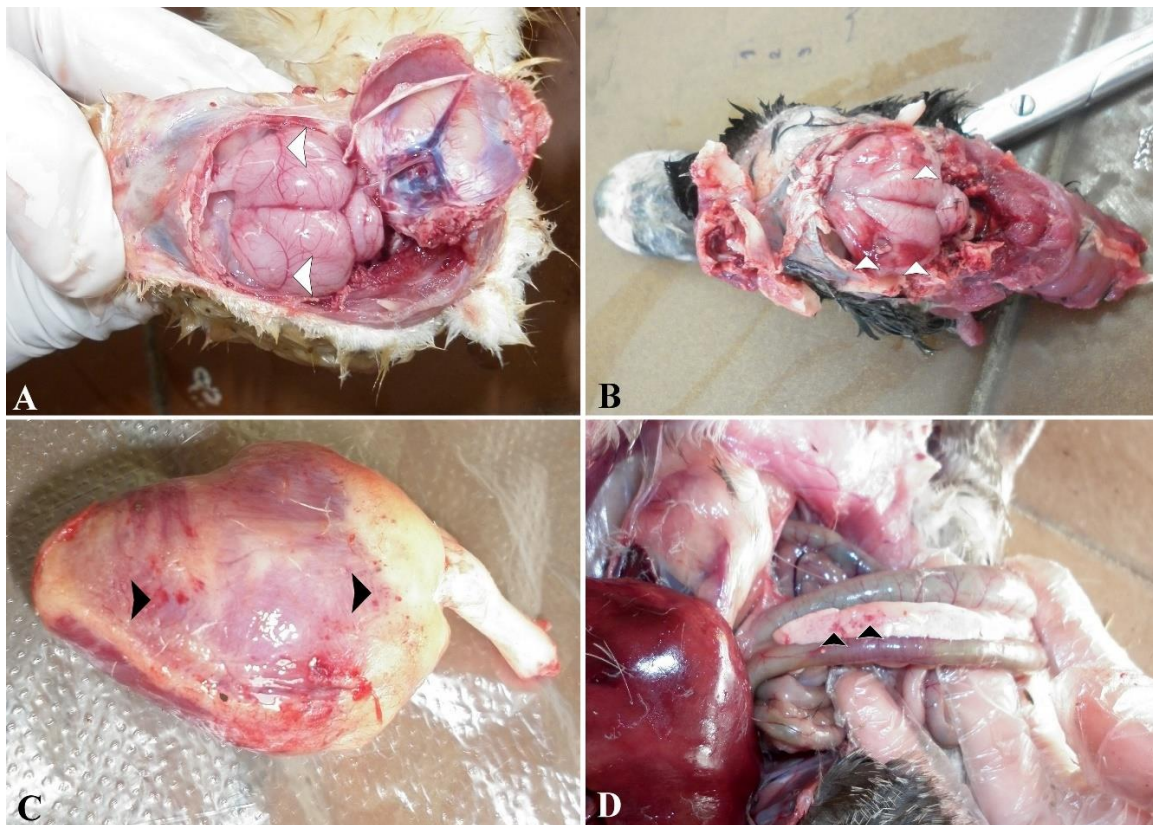


Figure 1: Muscovy ducks infected by HPAIV subtype H5N1. (A) Brain, showing severely congested meningeal vessels. (B) Brain, showing bilateral meningeal hemorrhage. (C) Heart, showing hemorrhages on coronary fat and epicardium. (D) Pancreas, showing petechial hemorrhages

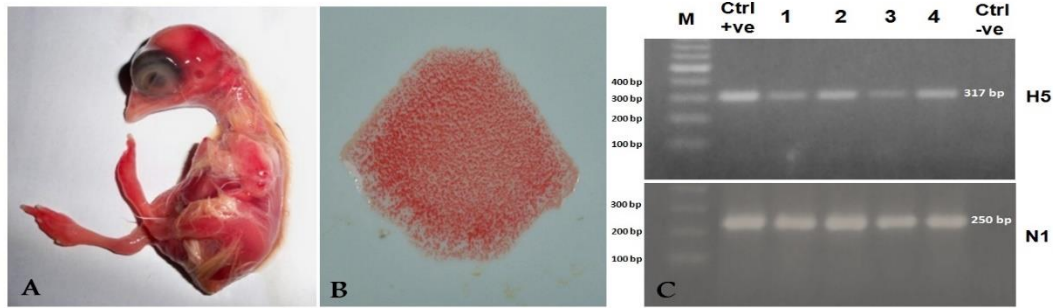


Figure 2: Virus isolation on embryonated chicken eggs and identification of AIV by RT-PCR. (A) Infected chicken embryos inoculated with the supernatants of processed brain of sampled ducks; the embryos died within 48 hrs with hemorrhages and congestion. (B) Infected allantoic fluids were screened with rapid HA assay for detection of hemagglutinating virus(s); positive hemagglutination of chicken RBCs. (C) PCR amplification for HA gene (upper) and NA gene (lower) showing bands of ~317 bp and 250 bp in size respectively. First lane: Molecular ladder, Lane 1-4: Positive samples, Ctrl +ve: Known Positive HPAIV H5N1, Ctrl-ve: Control negative

Case history, clinical signs and gross findings

The clinical signs of the examined ducks were torticollis, lack of coordination, seizures, greenish diarrhea, loss of appetite and sudden deaths. Within 2-3 days of the illness onset, the mortality rates were 37.5-63%. Gross examination revealed severely congested meningeal blood vessels, friable brain tissues (Fig. 1A) and bilateral meningeal hemorrhage (Fig. 1B) in 66.7% of examined ducks. The lungs appeared edematous, congested and severely hemorrhagic. Petechial hemorrhages on the coronary fat and the epicardium were observed (Fig. 1C) in 11% of diseased birds. Congested heart and hepatosplenomegaly were observed in 72% of birds. Petechial hemorrhages on the pancreas were seen in 22.2% of diseased ducks (Fig. 1D). Mild lesions consisting of petechial hemorrhages on the proventriculus, duodenum and ceca were observed in 16.7% of infected ducks.

Virus isolation and identification

The embryo mortalities in infected ECEs occurred within 24-72 hours post-inoculation. Depending upon embryo lesions (Fig. 2A) and mortality, 66.7% of examined duck samples showed evidence of AIV infection. The collected allantoic fluids demonstrated agglutination of RBCs in rapid HA assay (Fig. 2B) in 66.7% of ducks and further identified by

RT-PCR for HPAIV subtype H5N1 (Fig. 2C). The HPAIV was isolated from different duck tissues including, brain, lungs and intestine. Duck hepatitis virus type 1 infection was excluded in original liver tissues and allantoic fluids by the RT-PCR negative result.

Histopathology and immunohistochemistry

Lesions were observed mainly in the brain, liver and pancreas. The brain sections showed gliosis, extravasated erythrocytes in the neuropil (Fig. 3A) and perivascular lymphocytic cuffing with neuronal degeneration (Fig. 3B). The liver sections showed multiple focal lymphocytic aggregations particularly in the portal areas. Multiple focal lymphocytic aggregations were seen in the pancreas. Pulmonary edema and congestion of pulmonary blood vessels were observed. The findings were similar in all examined flocks. Pericarditis with multiple lymphocytic aggregates and hemorrhages were seen (Fig. 3C). Focal aggregations of lymphocytes in the submucosa of the proventriculus were also observed in few birds (Fig. 3D). Positive IHC staining was detected in the cytoplasm and the nucleus of the neurons, in the ependymal and glial cells of the brain (Fig. 3E) and in the submucosal Meissner's plexus neurons of the intestinal tissues (Fig. 3F). Viral antigen was also identified in the hepatic and Kupffer cells.

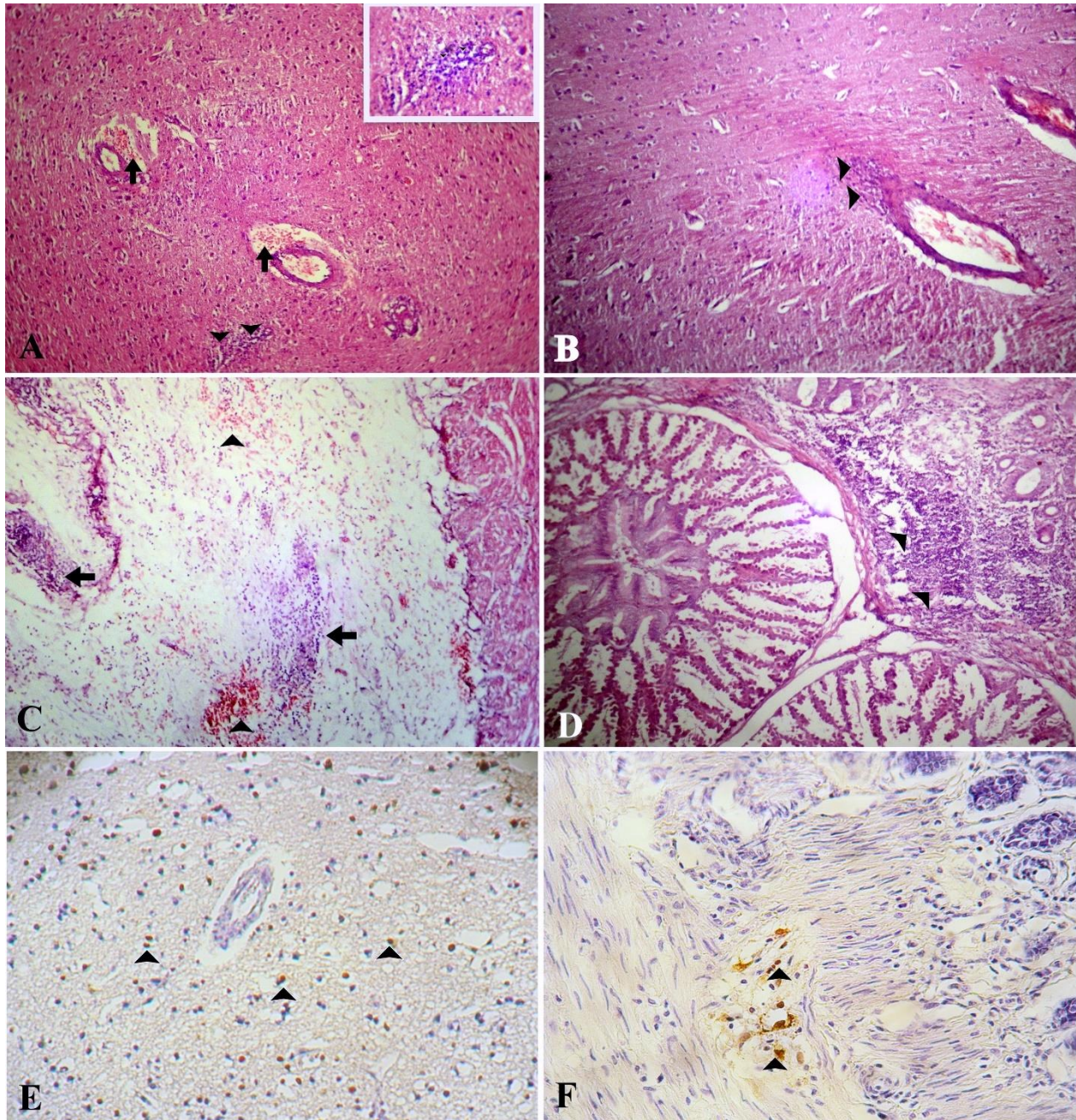


Figure 3: Microscopic lesions and positive viral antigen cells in naturally infected Muscovy ducks by HPAIV subtype H5N1. (A) Brain, extravasated erythrocytes in the neuropil (arrows) with focal glial cells proliferation (arrow heads), H&E X100; Inset: Higher magnification, H&E, X400. (B) Brain, perivascular lymphocytic cuffing (arrow heads) with neuronal degeneration, H&E X100. (C) Pericardium, severe edema with multiple focal lymphocytic aggregates (arrows) and hemorrhages (arrow heads), H&E X100. (D) Proventriculus, showing severe lymphocytic infiltrations in the submucosa (arrow heads), H&E X100. (E) Brain, positive immunostaining of the neurons and glial cell, IHC, X100. (F) Intestine, positive immunostaining of the submucosal Meissner's plexus neurons (arrow heads), IHC X100

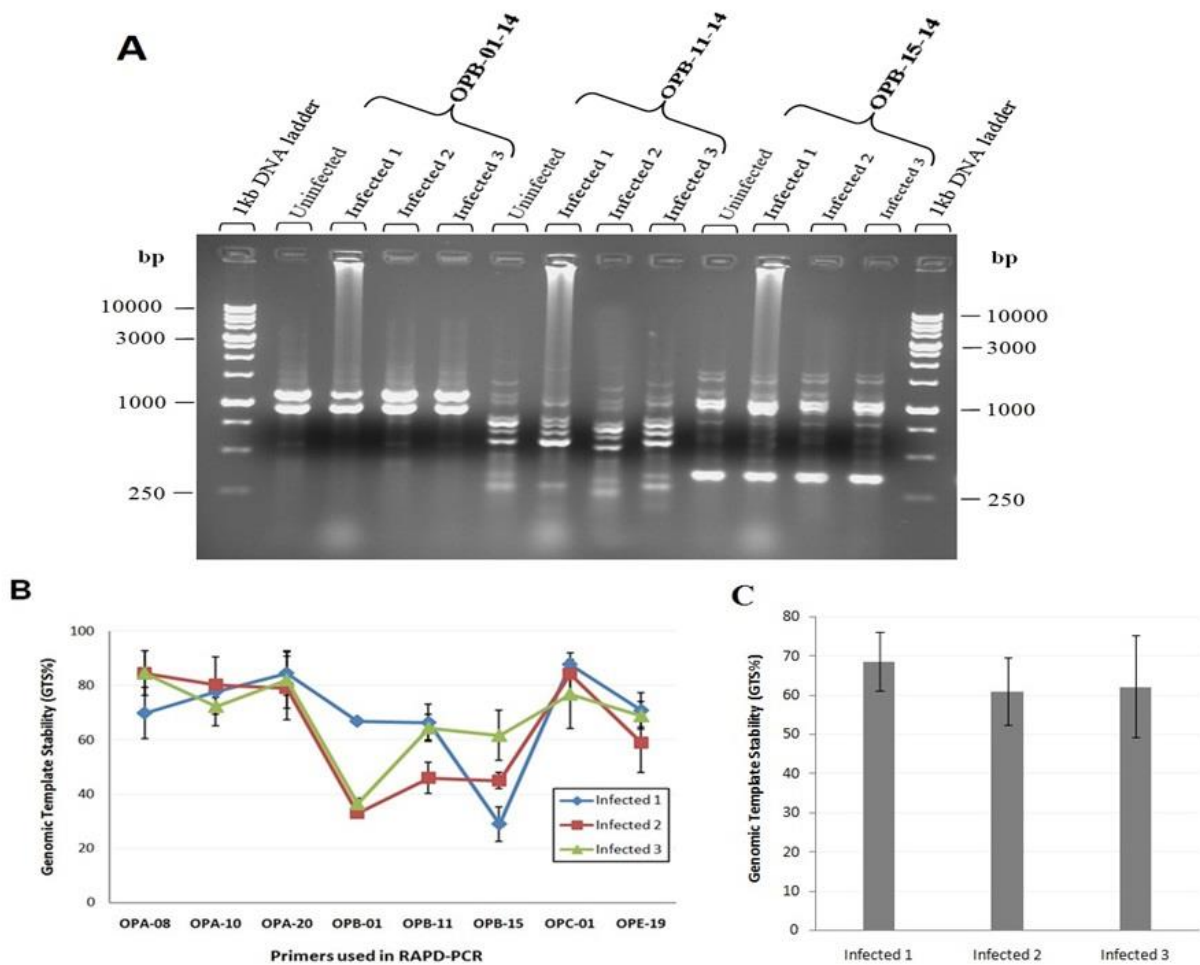


Figure 4: RAPD-PCR analysis of AIV infected at 24h (Infected 1), at 48h (Infected 2) and 72h (Infected 3) following appearance of clinical signs and uninfected Muscovy ducklings. (A) RAPD-PCR profiles of AIV infected and uninfected Muscovy ducklings. (B) Genomic template stability in brain of ducklings infected with AIV using different RAPD primers. The data shown are the mean \pm Standard errors (Error bars) of the mean values from nine infected ducks per each flock. (C) Changes of GTS in brain of ducklings infected with AIV in relation to uninfected ones. The data shown are the mean \pm Standard errors (Error bars) of the mean values from 8 primers

RAPD-PCR

The pooled DNAs from AIV infected ducks at 24h, 48h and 72h following appearance of clinical signs were further evaluated for any changes in comparison with uninfected ones. The gel electrophoresis showed the presence of numerous bands between 181 and 1980 bp (Fig. 4A). The variations in the RAPD profiles are expressed as reduction in GTS, a qualitative assessment refer to the change in the number of RAPD bands generated by infected ducks, regarding the profiles of uninfected ducks. The

GTS% in infected ducks was shown in Fig. 4B and 4C. The statistical analysis revealed no significant differences in GTS% in infected ducks at different time points.

Discussion

Overtime, HPAI H5N1 viruses have evolved and changed their pathogenicity in ducks (21,22) with more severe disease pattern in Muscovy ducks comparing with Pekin ducks (23-25). In Egypt, the role of ducks in virus evolution is still unknown and needs thoroughly investigation particularly after the

emergence of 2.2.1.2 clade in 2014-2015, where the ancestor virus of this clade maybe a duck-origin virus (26). This study focused on the natural outbreaks of HPAIV-H5N1, by exploring the macroscopic and microscopic lesions as well as distribution of viral antigen in tissues in Muscovy ducks along the last three years.

It has been shown that ostriches and turkeys infected with low pathogenic AI viruses were expressed age-related differences in susceptibility (27,28). Conversely, HPAI viruses produce elevated morbidity and mortality in gallinaceous domestic poultry regardless of age (11,29). In consistency, here, the natural infection with HPAIV in domestic Muscovy ducks induced severe lesion and rapid deaths with high mortality rate up to 63% in 6 days old ducklings. Systemic infection was demonstrated by isolation of the HPAIV from multiple duck tissues. The increased virulence of HPAIV in ducks interferes with the disease control such is explains by persistence of HPAI virus shedding for longer periods among vaccinated ducks. Consequently the virus can perpetuate through the surrounding environment with increasing the transmission opportunity to both birds and human (22,30).

In the present study, the infected ducks showed an indicative clinical picture for AIV and/or DHV-1; although the infection with DHV-1 was excluded by negative RT-PCR results. The commonly observed lesions in Muscovy ducks were necrotic pancreatitis beside meningoencephalitis. The capability of the HPAI H5N1 viruses to get entry to and replicate in duck brain tissue is likely to be a strong determinant in induction of morbidity and mortality (31,32). The findings in this study of high percentage of ducks (66.7%) showing nervous signs, beside high intensity of virus NP as noticed by IHC in the brain tissues, confirm the neurotropism affinity of AIV. Combination of neurological and myocardial dysfunction with multiorgan failure is involved in the pathogenesis of HPAI H5N1 viruses. Here, 11% of the affected ducks demonstrated gross and microscopic changes in the heart. Similar results were reported (33).

The current study shows that the viral nucleoprotein antigen was detected in the neurons and glial cells nuclei which strengths the speculation of virus replication in brains. Viral replication in other tissues was recognized by staining of viral antigen and associated histological lesions (34). The HPAI H5N1 virus formed a fulminating and speedy fatal systemic disease in gallinaceous birds experimentally infected with HK/220/97 (19). Revealing of viral nucleoprotein in the peripheral nervous system is not registered in the H5N1 naturally infected birds (35). Nonetheless, in our study, the nucleoprotein of H5N1 was detected in the intestinal submucosal plexus among other tissues indicating the pantropism affinity of H5N1 avian influenza viruses.

In Egypt, the outbreaks and high mortality in both chickens and domestic ducks are indicated by continuous circulation of HPAI H5N1 in both commercial and backyards poultry industry (26,36,37). We attempt to monitor the genetic changes in the brain of Muscovy ducks after AIV infection using RAPD-PCR. The loss of bands can reveal an alteration in the sequence of DNA caused by mutations which might be induced as a consequence of the infection (38). A loss of band at 380 bp was observed in ducks infected with AIV at 48 and 72 h following appearance of clinical signs with primer OPE-19-14 indicating changes in this genomic DNA region. Such variation in electrophoretic patterns reflect the DNA alterations which could be attributable to point mutations, or structural rearranging resulting from genotoxins, affecting the primer sites and/or interpriming distances (39-41). Also, presence of new PCR products could be the result of the instability of the genomic template correlated to the level of DNA damage, and the effectiveness of the DNA repair and replication (42,43). Interestingly, a unique band at 1700 bp was observed in ducks infected with AIV with primer OPB-01-14. Moreover, GTS%, statistical qualitative analysis, could allocate the correlation of genomic stability variations with AIV infection at different time points. Here, the GTS% in infected ducklings is $62.3\% \pm 1.76$ indicated the DNA alterations induced with

AIV infection in ducklings as early as 24 hour following appearance of clinical signs. Infection with influenza virus was accompanied by generation of excess reactive oxygen species (ROS) (44); so, specific oxidant sensitive pathway and apoptosis are activated (45). Consequently, further studies need to be done for measuring ROS release from AIV infected cells.

Conclusion

Generally, our findings indicate that HPAIV H5N1 is still circulating in Egypt amongst Muscovy backyard ducks causing high mortalities particularly in ducklings. Meanwhile, the RAPD profile analysis in conjunction with the evaluation of GTS% would prove a powerful investigation tool to monitor the genome changes following AIV infections. The study demonstrates the possible DNA alterations induced by AIV infections in brain tissues of ducks using the RAPD-PCR.

Conflicts of interest

All authors declare that they have no conflicts of interest.

References

1. Tong S, Zhu X, Li Y, Shi M, Zhang J, Bourgeois M, Yang H, Chen X, Recuenco S, Gomez J, Chen LM, Johnson A, Tao Y, Dreyfus C, Yu W, McBride R, Carney PJ, Gilbert AT, Chang J, Guo Z, Davis CT, Paulson JC, Stevens J, Rupprecht CE, Holmes EC, Wilson IA, Donis RO. New world bats harbor diverse influenza A viruses. *PLOS Pathogen* 2013; 9:e1003657.
2. Swayne DE, Suarez DL. Highly pathogenic avian influenza. *Revue Scientifique et Technique* 2000; 19: 463–82.
3. Abdelwhab EM, Selim AA, Arafa A, Galal S, Kilany WH, Hassan MK, Aly MM, Hafez MH. Circulation of avian influenza H5N1 in live bird markets in Egypt. *Avian Dis* 2010; 54: 911–4.
4. WHO. "H5N1 avian influenza: Timeline of major events." [Online]. Available: 2011; Accessed December 13, 2011.
5. Albrecht T, Fons M, Boldogh I, Rabson, AS. Effects on Cells. In: *Medical Microbiology*, 4th ed S Baron (ed) University of Texas Medical Branch at Galveston, Galveston (TX) publishers 1996; Chapter 44.
6. Kim JK, Negovetich NJ, Forrest HL, Webster RG. Ducks: the "Trojan horses" of H5N1 influenza. *Influenza and Other Respiratory Viruses* 2009; 3: 121–8.
7. Dugan VG, Chen R, Spiro DJ, Sengamalay N, Zaborsky J, Ghedin E, Nolting J, Swayne DE, Runstadler JA, Happ GM, Senne DA, Wang R, Slemons R, Holmes EC, Taubenberger JK. The evolutionary genetics and emergence of avian influenza viruses in wild birds. *PLoS Pathogen* 2008; 4(5):e1000076.
8. Abdelwhab EM, Arafa AS, Stech J, Grund C, Stech O, Graeber-Gerberding M, Beer M, Hassan MK, Aly MM, Harder TC, Hafez HM. Diversifying evolution of highly pathogenic H5N1 avian influenza virus in Egypt from 2006 to 2011. *Virus genes* 2012; 45: 14–23.
9. Arafa A, Suarez D, Kholosy SG, Hassan MK, Nasef S, Selim A, Dauphin G, Kim M, Yilma J, Swayne D, Aly MM. Evolution of highly pathogenic avian influenza H5N1 viruses in Egypt indicating progressive adaptation. *Arch Virol* 2012; 157: 1931–47.
10. El-Zoghby EF, Aly MM, Nasef SA, Hassan MK, Arafa AS, Selim AA, Kholosy SG, Kilany WH, Safwat M, Abdelwhab EM, Hafez HM. Surveillance on A/H5N1 virus in domestic poultry and wild birds in Egypt. *Virol J* 2013; 10: 203.
11. Swayne DE, Halvorson, DA. Influenza. In: *Diseases of poultry*, 12th ed YM Saif, JR Glisson, AM Fadly, LR McDougald, L Nolan (ed) Blackwell, Ames, Iowa 2008; 153–84.
12. Williams JGK, Kubelik AR, Livak KJ, Rafalski JA, Tingey SV. DNA polymorphism amplified by arbitrary primers are useful as genetic markers. *Nucleic Acids Res* 1990; 18: 6531–35.
13. Yamamoto K, Murakami R, Takamura Y. Differentiation of thermophilic anaerobic gram positive bacteria by random amplified polymorphic DNA analysis. *Microbes and Environments* 2001; 16: 91–9.
14. Mollah MBR, Islam FB, Islam MS, Ali MA, Alam MS. Analysis of genetic diversity in Bangladeshi chicken using RAPD markers. *Biotechnology* 2009; 8: 462–7.
15. OIE. "Manual of Diagnostic Tests and Vaccines for Terrestrial Animals (Chapter 2.3.4)." [Online]. Available: <http://www.oie.int/en/international-standard-setting/terrestrial-manual/access-online/>. 2012; Accessed May 25, 2013.
16. Njouom R, Aubin JT, Bella AL, Demsa BM, Rouquet P, Gake B, Ngangnou A, Foupoua-pouognigni Y, Van Der Werf S, Rocourt J, Rousset D. Highly pathogenic avian influenza virus subtype

H5N1 in ducks in the Northern part of Cameroon. *Vet Microbiol* 2008; 130: 380–4.

17. Tsukamoto K, Ashizawa T, Nakanishi K, Kaji N, Suzuki K, Shishido M, Okamatsu M, Mase M. Use of reverse transcriptase PCR to subtype N1 to N9 neuraminidase genes of avian influenza viruses. *J Clin Microbiol* 2009; 47: 2301–3.

18. Kim MC, Kwon YK, Joh SJ, Kwon JH, Kim JH, Kim SJ. Development of one-step reverse transcriptase-polymerase chain reaction to detect duck hepatitis virus type 1. *Avian Dis* 2007; 51: 540–5.

19. Perkins LEL, Swayne DE. Pathobiology of A/chicken/Hong Kong/220/97 (H5N1) avian influenza virus in seven gallinaceous species. *Vet Pathol* 2001; 38: 149–64.

20. Liu W, Yang YS, Zhou Q, Xie L, Li P, Sun T. Impact assessment of cadmium contamination on rice (*Oryza sativa* L.) seedlings at molecular and population levels using multiple biomarkers. *Chemosphere* 2007; 67:1155–63.

21. Phuong DQ, Dung NT, Jørgensen PH, Handberg KJ, Vinh NT, Christensen JP. Susceptibility of Muscovy (*Cairina moschata*) and mallard ducks (*Anas platyrhynchos*) to experimental infections by different genotypes of H5N1 avian influenza viruses. *Vet Microbiol* 2011; 148: 168–74.

22. Wasilenko JL, Arafa AM, Selim AA, Hassan MK, Aly MM, Ali A, Nassif S, Elebiary E, Balish A, Klimov A, Suarez DL, Swayne DE, Pantin-Jackwood MJ. Pathogenicity of two Egyptian H5N1 highly pathogenic avian influenza viruses in domestic ducks. *Arch Virol* 2011; 156: 37–51.

23. Cagle C, To TL, Nguyen T, Wasilenko J, Adams SC, Cardona CJ, Spackman E, Suarez DL, Pantin-Jackwood MJ. Pekin and Muscovy ducks respond differently to vaccination with a H5N1 highly pathogenic avian influenza (HPAI) commercial inactivated vaccine. *Vaccine* 2011; 29: 6549–57.

24. Cagle C, Wasilenko J, Adams SC, Cardona CJ, To TL, Nguyen T, Spackman E, Suarez DL, Smith D, Shepherd E, Roth J, Pantin-Jackwood MJ. Differences in pathogenicity, response to vaccination, and innate immune responses in different types of ducks infected with a virulent H5N1 highly pathogenic avian influenza virus from Vietnam. *Avian Dis* 2012; 56: 479–87.

25. Pantin-Jackwood M, Swayne DE, Smith D, Shepherd E. Effect of species, breed and route of virus inoculation on the pathogenicity of H5N1

highly pathogenic influenza (HPAI) viruses in domestic ducks. *Vet Res* 2013; 44: 62.

26. Arafa AS, Naguib MM, Luttermann C, Selim AA, Kilany WH, Hagag N, Samy A, Abdelhalim A, Hassan MK, Abdelwhab EM, Makonnen Y, Dauphin G, Lubroth J, Mettenleiter TC, Beer M, Grund C, Harder TC. Emergence of a novel cluster of influenza A (H5N1) virus clade 2.2.1.2 with putative human health impact in Egypt, 2014/15. *Euro Surveill* 2015; 20: 2–8.

27. Capua I, Marangon S, Selli L, Alexander DJ, Swayne DE, Pozza MD, Parenti E, Cancellotti FM. Outbreaks of highly pathogenic avian influenza (H5N2) in Italy during October 1997–January 1998. *Avian Pathol* 1999; 28: 455–60.

28. Capua I, Mutinelli F, Terregino C, Cattoli G, Manvell RJ, Burlini F. Highly pathogenic avian influenza (H7N1) in ostriches farmed in Italy. *Vet Rec* 2000; 146: 356.

29. Swayne DE, Pantin-Jackwood MJ. Pathogenicity of avian influenza viruses in poultry. *Dev Biol (Basel)* 2006; 124: 61–7.

30. Pfeiffer J, Pantin-Jackwood M, To T, Nguyen T, Suarez D. Phylogenetic and biological characterization of highly pathogenic H5N1 avian influenza viruses (Vietnam 2005) in chickens and ducks. *Virus Res* 2009; 142 :108–20.

31. Tang Y, Wu P, Peng D, Wang X, Wan H, Zhang P, Long J, Zhang W, Li Y, Wang W, Zhang X, Liu X. Characterization of duck H5N1 influenza viruses with differing pathogenicity in mallard (*Anas platyrhynchos*) ducks. *Avian Pathol* 2009; 38: 457–67.

32. Goletic T, Gagic A, Rešidbegovic E, Kustura A, Kavazovic A, Savic V, Harder T, Starick E, Prasovic S. Highly pathogenic avian influenza virus subtype H5N1 in mute swans (*Cygnus olor*) in central Bosnia. *Avian Dis* 2010; 54(1 Suppl): 496–501.

33. Pantin-Jackwood MJ, Suarez DL, Spackman E, Swayne DE. Age at infection affects the pathogenicity of Asian highly pathogenic avian influenza H5N1 viruses in ducks. *Virus Res* 2007; 130: 151–61.

34. Pantin-Jackwood MJ, Swayne DE. Pathobiology of Asian highly pathogenic avian influenza H5N1 virus infections in ducks. *Avian Dis* 2007; 51: 250–9.

35. Brøjer C, Ågren EO, Uhlhorn H, Bernodt K, Mörner T, Jansson DS, Mattsson R, Zohari S, Thorén P, Berg M, Gavier-Widén D. Pathology of natural highly pathogenic avian influenza H5N1 infection in wild tufted ducks (*Aythya fuligula*). *J Vet Diagn Invest* 2009; 21: 579–87.

36. Hagag IT, Mansour SM, Zhang Z, Ali AA, Ismaiel EM, Salama AA, Cardona CJ, Collins J, Xing Z. Pathogenicity of highly pathogenic avian influenza virus H5N1 in naturally infected poultry in Egypt. PLoS One 2015; 10: e0120061.
37. Mansour SMG, Ali H, ElBakrey RM, El-Araby IE, Knudsen DEB, Eid AAM. Co-infection of highly pathogenic avian influenza and duck hepatitis viruses in Egyptian backyard and commercial ducks. International Journal of Veterinary Science and Medicine 2018; doi.org/10.1016/j.ijvsm.2018.07.004
38. Rocco L, Valentino IV, Peluso C, Stingo V. Genomic Template Stability Variation in Zebrafish Exposed to Pharmacological Agents. IJEP 2013; 3: 1–6.
39. Atienzar FA, Venier P, Jha AN, Depledge MH. Evaluation of the random amplified polymorphic DNA (RAPD) assay for the detection of DNA damage and mutations. Mutat Res 2002; 521: 151–63.
40. Zhiyi R, Haowen Y. A method for genotoxicity detection using random amplified polymorphisms DNA with *Danio rerio*. Ecotoxicol Environ Saf 2004; 58: 96–103.
41. Atienzar FA, Jha AN. The random amplified polymorphic DNA (RAPD) techniques applied to genotoxicity and carcinogenesis studies: A critical review. Mutat Res 2006; 613: 76–102.
42. Atienzar FA, Cordi B, Evenden AJ. Qualitative assessment of genotoxicity using random amplified polymorphic DNA: comparison of genomic template stability with key fitness parameters in *Daphnia magna* exposed to benzo[a]pyrene. Environ. Toxicol Chem 1999; 18: 2275–82.
43. Rocco L, Izzo A, Zito G, Peluso C, Stingo V. Genotoxicity in zebrafish (*Danio rerio*) exposed to two pharmacological products from an impacted Italian river. J Environ Anal Toxicol 2011; 1: 103.
44. Akaike T, Noguchi Y, Ijiri S, Setoguchi K, Suga M, Zheng YM, Dietzschold B, Maeda H. Pathogenesis of influenza virus-induced pneumonia: Involvement of both nitric oxide and oxygen radicals. Proc Natl Acad Sci USA 1996; 93: 2448–53.
45. Brydon EW, Morris SJ, Sweet C. Role of apoptosis and cytokines in influenza virus morbidity. FEMS Microbiol Rev 2005; 29: 837–50.