

The Diagnostic Accuracy of Radiographic Cardiac Indices in the Assessment of Cardiomegaly and Left Atrial Enlargement in Rats With Dilated Cardiomyopathy: An Experimental Study

Key words

dilated cardiomyopathy;
doxorubicin;
VHS;
RLAD;
VLAS;
rat

Mahir Kaya^{1*}, Mehmet Alper Çetinkaya²

¹Medical Imaging Techniques Program, Health Services Vocational College, Akdeniz University, ²Laboratory Animal Research and Application Center, Hacettepe University, Turkey

*Corresponding author: kayamahir@gmail.com

Abstract: The purpose of this study was to determine the diagnostic value of the vertebral heart score (VHS), radiographic left atrial dimension (RLAD), and vertebral left atrial size (VLAS) in the radiographic evaluation of doxorubicin-induced dilated cardiomyopathy (DCM) in rats. The animals were allocated into two experimental groups, a DCM group (n=100), which received weekly injections of doxorubicin (2 mg/kg per dose intraperitoneally [ip]) over nine weeks, and a control group (n=18) receiving an appropriate volume of 0.9% saline ip. Radiographic cardiac indices (VHS, RLAD, VLAS) were measured two weeks after the final injection, and cardiac morphological parameters (heart weight [HW], heart weight:body weight ratio [HBW], and heart weight:tibial length ratio [HTL]) were determined after sacrifice in all surviving rats (17 control and 54 DCM). Correlations were calculated between the indices and parameters, as well as their sensitivity and specificity in detecting cardiomegaly and left atrial enlargement (LAE) with the three classifiers ($HW \leq 0.96$ g, $HBW \leq 235$, and $HTL \leq 201$). A powerful negative correlation was observed between the indices and parameters ($r_s \geq -0.711$, $P < 0.001$). Area under the curve values were 0.989 for RL-VHS, 0.992 for DV-VHS, 0.971 for RLAD, and 0.948 for VLAS. The sensitivity and specificity of these indices in detecting cardiomegaly and LAE at the optimal cut-off values were 94.4% and 100%, respectively, at 8.8 vertebrae (v) for RL-VHS and DV-VHS, 96.3% and 94.1% at 1.4v for RLAD, and 94.4% and 88.2% at 2.1v for VLAS. Radiographic cardiac indices offer an accurate and repeatable method for predicting cardiomegaly and LAE in rats with DCM.

Received: 31 January 2023
Accepted: 7 July 2023

Introduction

Exotic animal practice is one of the fastest-growing disciplines in veterinary medicine (1). As with other pet animals, specific medical tests, including diagnostic imaging, are now both a requirement in small exotic mammals and also specifically requested by their owners. Similar to other exotic animals (2), heart diseases are also observed in pet rats (3). Left ventricular hypertrophy, left atrial enlargement (LAE), diastolic dysfunction, and heart failure with pulmonary congestion can be seen in addition to spontaneous

cardiomyopathy associated with the presence of aging-related left atrioventricular thrombus in rats (4, 5). Dilated cardiomyopathy (DCM) has been reported in pet rats (6).

DCM is a primary myocardial disease mainly characterized by cardiac chamber dilation, resulting in impaired systolic and diastolic function. The use of the anthracycline drug doxorubicin as a chemotherapeutic agent frequently induces myocardial toxicity, making it an optimal and widely used

experimental model for DCM (7, 8). The reference model of chronic doxorubicin-induced DCM was initially described in rabbits (9). This model has also been used in rats and has shown to be successful in inducing not only morphological changes but also cardiac remodeling and systolic and diastolic left ventricular dysfunction (8).

Although echocardiography is a well-established method for assessing cardiac structure and function in both human and veterinary medicine (10), it is not used routinely in pet rats (11). Heart size and left atrial dimension can be evaluated using radiographic cardiac indices including vertebral heart score (VHS) (12), vertebral left atrial size (VLAS) (13), and radiographic left atrial dimension (RLAD) (14). While these indices have also been described for healthy rats (11, 15), they have not to date been reported for rats with DCM.

The purpose of this study was to determine the diagnostic value of VHS, RLAD, and VLAS in the radiographic evaluation of doxorubicin-induced DCM in rats.

Materials and methods

Animals

One hundred eighteen adult male Wistar albino rats (n=118, weight 280-360 g) were housed in the Akdeniz University Experimental Research and Application Center (Türkiye) in groups of four to six animals at 50-60% humidity and 20-21°C in a 12-h dark/light cycle. Standard rat chow and free access to water were provided. The study was conducted in compliance with the national guidelines for the Care and Use of Laboratory Animals. The experimental protocol was approved by the Akdeniz University animal care ethics committee (no. B.30.2.AKD.0.05.07.00/111). The rats were randomly divided into two groups; control (n=18) and DCM (n=100), before drug or saline injection.

Experimental protocol

Adriamycin (doxorubicin chloride) was purchased from Saba (Istanbul, Türkiye) and dissolved in saline (10 mg/100 ml). It was then injected (2 mg/kg per dose) weekly via the intraperitoneal (ip) route over a period of nine weeks (cumulative dose 18 mg/kg) for the induction of DCM (7, 8). A control group was constituted consisting of animals of matched body weight receiving an appropriate volume of 0.9% saline ip over nine weeks. All surviving rats (17 control and 54 DCM) were subjected to radiographic examination two weeks after the last drug or saline injection.

Radiographic procedures

All surviving rats were then anesthetized using a combination of ketamine (75 mg/kg, Ketazol, Richter Pharma-Interhas, Türkiye) and xylazine HCl (5 mg/kg, Xylazine Bio, Bioveta-Interhas, Türkiye) administered ip.

RL contrast radiographs were obtained by means of a bolus injection of 0.5 ml of non-ionic opaque contrast agent (300 mg I/ml Iohexol, Omnipaque®, Opakim, Türkiye) from the tail vein. Exposure was performed as soon as the injection of the contrast agent was completed (15). For DV projection, the animal was immediately placed onto another cassette in the sternal position, and the thoracic region was imaged under the same exposure conditions.

Radiographic images obtained using a computed radiography reader (FCR Prima T2®, FujiFilm, Tokyo, Japan) were stored for subsequent use. These radiographic images were anonymized and randomized, and then evaluated by two observers using commercially available computer software (Image Intelligence™, FujiFilm, Tokyo, Japan). The observers, both with more than 20 years' veterinary experience, were blinded to the groups, and the body weight (BW), heart weight (HW), and tibial length (TL) of each rat. They were able to manipulate the images as required, including by changing the window width, window level, and magnification, and the radiographic cardiac indices were measured. Intra-observer agreement for all radiographic measurements was determined with one observer (MK) performing measurements on two separate occasions on 10 randomly selected rats from each group. Inter-observer variability was determined by two observers (MK and MAÇ) completing all radiographic measurements for the same 20 rats.

Measurements of radiographic cardiac indices

VHS was measured as described by Buchanan (2000) (16). On RL view, the cardiac long (L) axis was measured from the tracheal bifurcation to the cardiac apex. The cardiac short (S) axis was determined by measuring the distance from the intersection of the caudal border of the heart with the dorsal border of the CaCV to the cranial border of the heart. Commercially available computer software was used to apply 90° rotation between the L and S axes (Figure 1A1 and 1B1). On DV view, the L axis was determined by measuring the distance from the intersection of the right mediastinal border with the silhouette of the heart to the apex. The S axis was defined as the widest measurement obtained perpendicular to the L axis (Figure 1A2 and 1B2). These two axes were then repositioned over the thoracic vertebrae from the cranial edge of T4, parallel to the vertebral column, and each length was then expressed in terms of the number of thoracic vertebrae (v), to the nearest 0.1v. The sums of vertebral numbers on the L and S axes obtained from RL and DV views were used as RL-VHS and DV-VHS, respectively.

RLAD was obtained as described by Sanchez Salguero et al. (2018) (14). A line bisecting the 90° angle at the junction of the RL-VHS, and L and S axes was extended from there to the radiographic projection of the dorsocaudal edge of the LA. Computer software was employed in order to establish a 45° angle between this line and the junction of

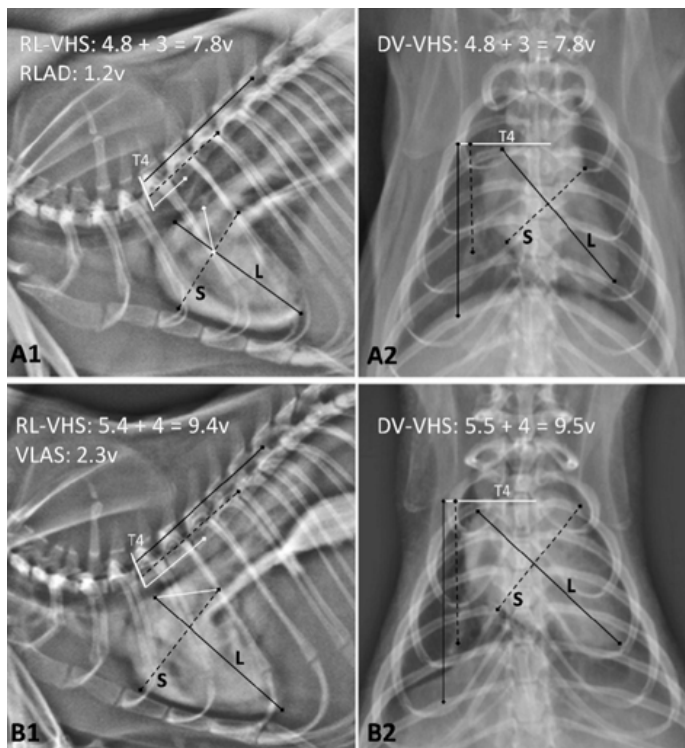


Figure 1: Contrast right lateral (RL) and dorsoventral (DV) thoracic radiographs (parameters: 65 kVp, 8 mA, 0.1 s, 30-cm film-focus distance) at 2 weeks after the last DOX dose or saline injection from two rats in the control (A) and dilated cardiomyopathy (B) groups. A and B- The black line (L) represents the long axis of the heart, and the dashed black line (S) represents the short axis. The vertebral heart score (VHS) was obtained from the total of S and L converted into vertebral values (v) by moving from the cranial margin of the 4th thoracic vertebra in a caudal direction. A1- The radiographic left atrial dimension (RLAD) was obtained by converting the measurement (white line) from the intersection of the L and S axes to the dorsal wall of the left atrium (LA) at a 45° angle into a vertebral value, as in VHS. B1- The white line represents the distance from the ventral of the tracheal bifurcation to the intersection of the caudal edge of the left atrium with the caudal vena cava. Similarly to RLAD, vertebral left atrial size (VLAS) was obtained by converting this measurement into a v value

the L and S axes (Figure 1A1). Similar to the VHS, the same line was then positioned over the thoracic vertebrae beginning, at the cranial edge of T4, and the number of vertebral units was estimated to the nearest 0.1 vertebral body length (Figure 1A1).

VLAS was obtained as described by Malcom et al. (2018) (13). A line was measured from the tracheal bifurcation to the most caudal aspect of the LA at the junction with the dorsal border of the CaVC. The same line was normalized to v, beginning from the cranial edge of T4, similar to VHS and RLAD (Figure 1B1).

Cardiac morphological parameters

Once the radiographic cardiac indices had been measured, all rats under ketamine-xylazine anesthesia were weighed and sacrificed via a thoraco-abdominal incision. The heart was removed, washed in ice-cold saline, and then weighed. Tibial length (TL) was measured from the mediolateral view of the right tibia. HW was divided by the BW and TL

to yield heart weight:body weight ratio (HBW) and heart weight:tibial length ratio (HTL) values for each rat.

Statistical methods

Statistical analysis was performed on commercial software (IBM SPSS Statistics 22.0, SPSS Inc., USA). Descriptive statistics were generated, and the Shapiro-Wilk test was applied to evaluate the normality of the distribution of continuous data. BW, HW, HBW, TL, HTL, RL-VHS, DV-VHS, RLAD, and VLAS values are presented as median and interquartile ranges (IQR). Comparisons between the control and DCM groups were performed using the Mann-Whitney U test. Spearman's rank-order correlation coefficient (rs) was applied to evaluate correlations between cardiac morphological parameters (HW, HBW, and HTL) and radiographic cardiac indices (RL-VHS, DV-VHS, RLAD, and VLAS). The following indices were used to evaluate this relationship for this analysis: an rs value from -1.0 to -0.7 was regarded as indicating strong negative correlation, values from -0.7 to -0.3 negative correlation, values from -0.3 to +0.3 small correlation or no association, values from +0.3 to +0.7 weak positive correlation, and values from +0.7 to +1.00 strong positive correlation. ROC curves, and the area under the curves (AUC) with 95% confidence intervals (CI) were generated for each radiographic cardiac index using $HW \leq 0.96$ g, $HBW \leq 235$, and $HTL \leq 201$ as the classifiers. The AUC values of the four measurements were compared using Delong's method (17) (MedCalc® Statistical Software version 20.115, 2022, MedCalc Software Ltd., Ostend, Belgium). Sensitivity and specificity for each radiographic cardiac index were determined with the Youden index in order to determine optimal cut-off values. Intra- and inter-observer variabilities were assessed for each radiographic cardiac index by means of intraclass correlation coefficient (ICC) estimates and 95% confidence intervals based on a single rater, absolute agreement, and a two-way random (inter-observer) and mixed (intra-observer) effect. ICC values >0.9 were regarded as excellent, 0.75 to 0.9 as good, 0.5 to 0.75 as moderate, and values <0.5 as poor (18). P values <0.05 were regarded as statistically significant.

Results

The mortality rate in the DCM group was 46% ($n=46/100$), while one animal from the control group ($n=1/18$, 5.6%) died.

Significant decreases in terminal BW and cardiac morphological parameters (HW, HBW, and HTL) and significant increases in radiographic cardiac indices (VHS, RLAD, and VLAS) were observed in the DCM group compared to the control group ($P<0.001$). The change in TL was not statistically significant ($P=0.246$) (Table 1).

The degrees of association between the radiographic cardiac indices and cardiac morphological parameters for all rats enrolled in the study are presented in Table 2. A strong

Table 1: Descriptive data for the radiographic cardiac indices (VHS, RLAD, and VLAS) and cardiac morphological parameters (HW, HBW, and HTL) between the control and DCM groups

Variables	Groups			
	Control		DCM	
	Median	IQR	Median	IQR
Terminal BW (g)	483	447-521	425*	355-460
HW (g)	1.17	1.09-1.27	0.9*	0.84-0.96
HBW ([mg/g]100)	244	232-259	211*	193-235
TL (cm)	4.59	4.30-4.81	4.51 ^{ns}	4.25-4.79
HTL (mg/cm)	260	245-278	198*	185-201
RL-VHS	8	7.5-8.9	9.1*	8.7-9.6
DV-VHS	8.2	7.6-9	9.2*	8.7-9.9
RLAD	1.2	1-1.5	1.7*	1.5-2.1
VLAS	1.9	1.6-2.2	2.3*	2.1-3.1

Data are presented in median and interquartile ranges (IQR) unless stated otherwise. ns, not significant P=0.246.

*Values within a row differ significantly (P<0.001) from that of the control group. Abbreviations: DCM, dilated cardiomyopathy; BW, body weight; HW, heart weight; HBW, heart weight:body weight ratio; TL, tibial length; HTL, heart weight: tibial length; RL-VHS, right lateral vertebral heart size; DV-VHS, dorsoventral vertebral heart size; RLAD, radiographic left atrial dimension; VLAS, vertebral left atrial size

negative correlation was determined between these indices and parameters ($r_s \geq -0.711$, $P < 0.001$).

Diagnostic accuracy, cut-offs, and likelihood ratios for RL-VHS, DV-VHS, RLAD, and VLAS in the radiographic prediction of cardiomegaly and LAE as determined by the three classifiers ($HW \leq 0.96$ g, $HBW \leq 235$, and $HTL \leq 201$) in the 71 rats are summarized in Table 3. Since two animals from the control group and one from the DCM group did not meet all these three classifiers, these were not included in the ROC analyses (15 control, 53 DCM). The ROC curve, AUC,

and cut-off values for the radiographic cardiac indices are shown in Figure 2. The ROC analyses indicated that all radiographic cardiac indices were useful in identifying rats with cardiomegaly and LAE due to DCM. AUC values were similar for RL-VHS (0.989), DV-VHS (0.992), RLAD (0.971), and VLAS (0.948). The optimal cut-off values for VHS, RLAD, and VLAS with the greatest sensitivity and specificity for detecting cardiomegaly and LAE were 8.8v, 1.4v, and 2.1v respectively. Sensitivity and specificity for both RL-VHS and DV-VHS were 94.4% and 100%, compared to

Table 2: Spearman correlation coefficients (rs)* quantifying the degree of association between radiographic and cardiac morphological variables in 71 rats

Radiographic variable	Cardiac morphological variable		
	HW	HBW	HTL
RL-VHS	-0.830	-0.755	-0.790
DV-VHS	-0.825	-0.711	-0.782
RLAD	-0.868	-0.731	-0.810
VLAS	-0.841	-0.727	-0.784

Abbreviations: HW, heart weight; HBW, heart weight:body weight ratio; HTL, heart weight:tibial length ratio; RL-VHS, right lateral vertebral heart size; DV-VHS, dorsoventral vertebral heart size; RLAD, radiographic left atrial dimension; VLAS, vertebral left atrial size, * All P<0.0001

Table 3: Receiver operating characteristic curve analyses for determining the diagnostic accuracy of the radiographic variable cut-offs for radiographic prediction of cardiomegaly and LA enlargement due to dilated cardiomyopathy when heart weight ≤ 0.96 g, heart weight:body weight ratio ≤ 235 , and heart weight:tibial length ratio ≤ 201 were adopted as criteria in 68 rats

Radiographic variables	AUC (95% CI)	z and P values	Cutoff (vertebrae)	Sn (%)	Sp (%)	+LR	-LR	Youden Index J
RL-VHS	0.989 \pm 0.001 0.929-1.00	51.467 < 0.0001	> 8.8	94,44	100.00	n/a	0.056	0.944
DV-VHS	0.992 \pm 0.008 0.934-1.00	64.981 < 0.0001	> 8.8	94.44	100.00	n/a	0.059	0.7706
RLAD	0.971 \pm 0.019 0.901-0.996	25.135 < 0.0001	> 1.4	96.30	94.12	16.37	0.039	0.9041
VLAS	0.948 \pm 0.031 0.867-0.986	14.503 < 0.0001	> 2.1	94,44	88.24	8.03	0.063	0.8268

Abbreviations: AUC, area under the curve; CI, confidence interval; Sn, sensitivity; Sp, specificity; +LR, positive likelihood ratio; -LR, negative likelihood ratio; RL-VHS, right lateral vertebral heart size; DV-VHS, dorsoventral vertebral heart size; RLAD, radiographic left atrial dimension; VLAS, vertebral left atrial size

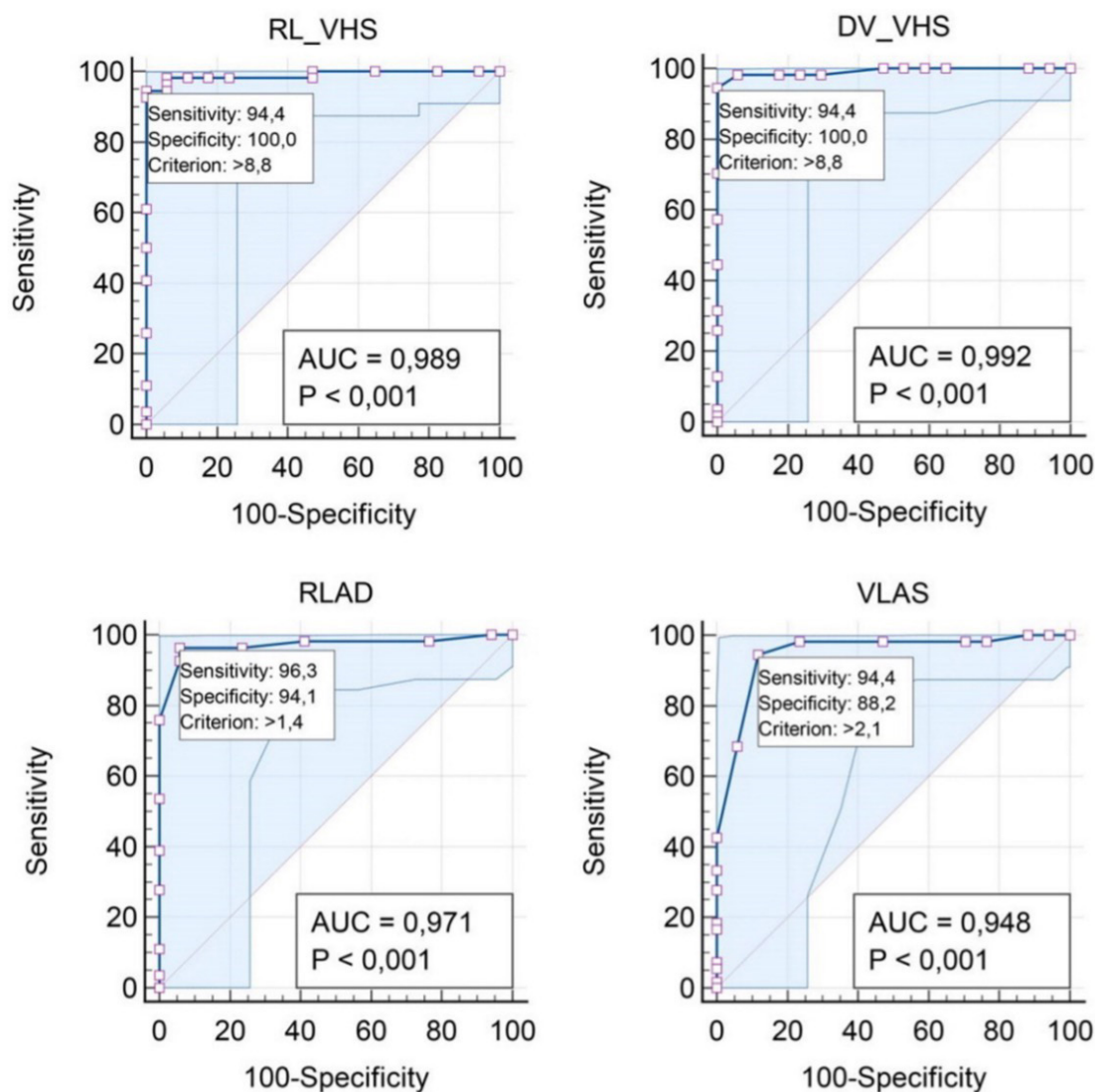


Figure 2: Receiver-operating characteristic curves and areas under the curve (AUC) for variables right lateral (RL)-vertebral heart score (VHS), dorsoventral (DV)-VHS, radiographic left atrial dimension (RLAD), and vertebral left atrial size (VLAS) to differentiate rats with the heart weight ≤ 0.96 g, heart weight:body weight ratio ≤ 235 , and the heart weight:tibial length ratio ≤ 201 . The RL-VHS, DV-VHS, RLAD, and VLAS optimal cutoff values which provided the greatest sensitivity and specificity along their respective curves are shown

96.3% and 94.1% for RLAD and 94.4% and 88.2% for VLAS, respectively.

Both intra- and inter-observer variabilities assessed using ICC values demonstrated good to excellent agreement for all radiographic cardiac indices (ICC>0.75, P<0.05) (Table 4).

Discussion

This study describes objective measurements (VHS, RLAD, and VLAS) for estimating cardiomegaly and LAE in rats with DCM using thoracic radiographs.

The heart silhouette from thoracic radiographs in animals can be objectively evaluated by means of VHS. VLAS and RLAD have been employed in the radiographic diagnosis of LAE in dogs in recent years. However, the cranial cardiac border on lateral thoracic plain radiographs in rats is unclear due to the opacity of the soft tissue in the cranial mediastinum. This radiographic feature in rats can lead to erroneous VHS values being obtained, especially by inexperienced operatives. Lateral thoracic contrast radiography, a simple and complication-free method, has been shown to be more effective than thoracic plain radiography, and that the heart can be evaluated with radiographic indices independently of the heart silhouette (15). Lateral thoracic contrast radiographs were therefore employed in the present study.

Short-term (19, 20) and long-term (7-9) doxorubicin injection models are generally used for the induction of DCM and heart failure. Although cardiac dysfunction and irregularity in cardiac functions have been documented using the Langendorff preparation of myocardial contractility in a short-term model in which high-dose anthracyclines were used for less than two weeks, functional and structural cardiac changes, cardiac function and remodeling consistent with DCM have not been confirmed with in vivo

imaging techniques. Nonetheless, both changes in cardiac morphology and also cardiac remodeling and left ventricular systolic dysfunction have been shown to be induced in rats in long-term injection models over an 8-12 week period (8). A long-term injection model was therefore employed in this study. However, since doses exceeding 1 mg/kg result in heart failure due to cardiotoxicity associated with the dose of doxorubicin used, they yield the classic symptoms of DCM, but similarly to the present study (46%), they also cause mortality rates of between 32% and 82% (8, 9, 19, 20). Mortality is associated with acute heart failure resulting from cardiotoxicity, although other factors reducing survival rates include nephrotoxicity, hepatotoxicity, and severe gastrointestinal bleeding (8, 21, 22).

A decrease in cardiac morphological parameters (HW, HBW, and HTL) is widely regarded as indicating cardiac atrophy in experimental studies involving doxorubicin (23-25). At the same time, a powerful correlation exists between HW and the echocardiographic left ventricular mass index (26). In addition, the cardiac morphological parameters used in the present study decreased significantly compared to the control group, and a strong negative correlation was determined between these parameters and the radiographic cardiac indices (P<0.001) (Table 2). The three cardiac morphological parameters (HW≤0.96 g, HBW≤235, and HTL≤201) were thus used as classifiers for ROC curve and AUC analysis of the radiographic variables. In our previous study (32), when HBW≥293 was employed as a criterion for radiographic prediction of cardiomegaly and LEA in rats developing eccentric cardiac hypertrophy due to volume overload, the AUC and cut-off values obtained were similar to the results of the present research (Table 3). Compared with our results, other studies using echocardiographic the left atrial-to-aortic root ratio (LA:Ao≥1.6) and normalized left ventricular end-diastolic dimension (LVIDDN≥1.7) as cardiomegaly and LAE criteria in dogs with degenerative mitral valve disease (13, 14, 27-29) have reported higher cut-off values (≥10.7 to >11.7 for VHS, ≥1.7 to ≥1.8 for RLAD, and 2.3 to ≥2.4 for VLAS) despite lower AUC values (0.81 to

Table 4: Intra- and inter-observer agreements for RL-VHS, DV-VHS, RLAD, and VLAS in rats

Radiographic variable		Intra-observer agreement			Inter-observer agreement		
		ICC	95% CI	P value	ICC	95% CI	P value
RL-VHS	Control	0.92	0.58-0.98	<0.01	0.87	0.48-0.97	<0.01
	DCM	0.83	0.48-0.92	<0.01	0.78	0.40-0.93	<0.01
DV-VHS	Control	0.90	0.59-0.93	<0.01	0.82	0.55-0.97	<0.01
	DCM	0.88	0.36-0.94	<0.01	0.86	0.60-0.97	<0.01
RLAD	Control	0.90	0.71-0.95	<0.001	0.88	0.68-0.93	<0.001
	DCM	0.86	0.55-0.95	<0.001	0.90	0.59-0.96	<0.001
VLAS	Control	0.95	0.79-0.98	<0.001	0.91	0.74-0.97	<0.001
	DCM	0.91	0.77-0.97	<0.001	0.90	0.72-0.96	<0.001

Abbreviations: DCM, dilated cardiomyopathy; RL-VHS, right lateral vertebral heart size; DV-VHS, dorsoventral vertebral heart size; RLAD, radiographic left atrial dimension; VLAS, vertebral left atrial size

0.94 for VHS, 0.93 to 0.99 for RLAD, 0.84 to 0.95 for VLAS). In contrast to dogs, such echocardiographic criteria have not been reported in either experimental cardiological rat studies, or in pet rats. Although cardiac morphological parameters are regarded as useful in experimental DCM studies, compared with echocardiography, magnetic resonance imaging, or computed tomography (30–33), they are not a true gold standard method in determining radiographic cardiac index cut-off values. In addition, there is a small limit to our study in that only adult males from one rat strain are used; therefore, the cut-off values may differ in females, juveniles, or other strains. Nevertheless, our results should constitute a useful tool for comparison in future studies with both more advanced diagnostic methods and gender, age, and strain of rats, and can also be used to predict cardiomegaly and LAE in rats with DCM.

Inter-observer variability has been described as one of the factors impacting on radiographic cardiac indices (34, 35). Consistent with previous studies (11, 15, 28, 29, 36), good to excellent agreement was observed in intra- and inter-observer variabilities for all radiographic cardiac indices in the present research (Table 4).

Conclusions

Radiographic cardiac indices exhibiting powerful negative correlation with the cardiac morphological parameters employed as a marker of cardiac atrophy exhibited high sensitivity and specificity in predicting cardiomegaly and LAE resulting from DCM in rats. The recommended cut-off values (8.8v for VHS, 1.4v for RLAD, and 2.1v for VLAS) can be used for this purpose in both pet rats and in rat models of DCM.

Acknowledgements

The authors declare that they have no conflict of interest.

This research was not financially supported by any public, commercial, or nonprofit entity.

The authors express special thanks to Pharmacist Emin Egemen Seyhan for his friendly assistance in obtaining some of the drugs (Adriamycin) used in this study.

References

- Mayer J, Martin J. Barriers to exotic animal medicine. *Vet Clin North Am Exotic Anim Pract* 2005; 8: 487–6.
- Orcutt CJ, Malakoff RL. Cardiovascular disease. In: Quesenberry KE, Orcutt CJ, Mans C, Carpenter JW, eds. 4th ed. *Ferrets, rabbits and rodents: clinical medicine and surgery*. Elsevier: Missouri, 2020: 250–57.
- Sharp P, Villano J. Important biological features. In: Sharp P, Villano J, eds. *The laboratory rat*. 2nd ed. CRC Press: Boca Raton, 2012: 64–127.
- McInnes EF. Wistar and Sprague-Dawley rats. In: McInnes EF, ed. *Background lesions in laboratory animals a color atlas*. Elsevier: Missouri, 2011: 17–36.
- Mesquita TRR, Zhang R, Couto G, et al. Mechanisms of atrial fibrillation in aged rats with heart failure with preserved ejection fraction. *Heart Rhythm* 2020; 17: 1025–33.
- Dias S, Anselmi C, Casanova M, Planellas M, Martorell J. Clinical and pathological findings in 2 rats (*Rattus norvegicus*) with dilated cardiomyopathy. *J Exot Pet Med* 2017; 26: 205–12.
- Coutinho E Silva RDC, Zanoni FL, Simas R, et al. Effect of bilateral sympathectomy in a rat model of dilated cardiomyopathy induced by doxorubicin. *J Thorac Cardiovasc Surg* 2020; 160: e135–e44. doi: 10.1016/j.jtcvs.2019.09.031
- O’Connell JL, Romano MMD, Campos Pulici EC, et al. Short-term and long-term models of doxorubicin-induced cardiomyopathy in rats: a comparison of functional and histopathological changes. *Exp Toxicol Pathol* 2017; 69: 213–9.
- Jaenke RS. An anthracycline antibiotic-induced cardiomyopathy in rabbits. *Lab Invest* 1974; 30: 292–304.
- Coatney RW. Ultrasound imaging: principles and applications in rodent research. *ILAR J* 2001; 42: 233–47.
- Dias S, Anselmi C, Espada Y, Martorell J. Vertebral heart score to evaluate cardiac size in thoracic radiographs of 124 healthy rats (*Rattus norvegicus*). *Vet Radiol Ultrasound* 2021; 62: 394–401.
- Buchanan JW, Bucheler J. Vertebral scale system to measure canine heart size in radiographs. *J Am Vet Med Assoc* 1995; 206: 194–9.
- Malcom EL, Visser LC, Phillips KL, Johnson LR. Diagnostic value of vertebral left atrial size as determined from thoracic radiographs for assessment of left atrial size in dogs with myxomatous mitral valve disease. *J Am Vet Med Assoc* 2018; 253: 1038–45.
- Sanchez Salguero X, Prandi D, Labres-Diaz F, et al. A radiographic measurement of left atrial size in dogs. *Ir Vet J* 2018; 71: e25. doi: 10.1186/s13620-018-0137-x
- Çetinkaya MA, Kaya M. Radiographic cardiac indices for the evaluation of cardiac and left atrial sizes in healthy Wistar albino rats (*Rattus norvegicus*). *Thai J Vet Med* 2022; 52: 485–92.
- Buchanan JW. Vertebral scale system to measure heart size in radiographs. *Vet Clin North Am Small Anim Pract* 2000; 30: 379–93.
- DeLong ER, DeLong DM, Clarke-Pearson DL. Comparing the areas under two or more correlated receiver operating characteristic curves: a nonparametric approach. *Biometrics* 1998; 44: 837–45.
- Koo TK, Li MY. A guideline of selecting and reporting intraclass correlation coefficients for reliability research. *J Chiropr Med* 2016; 15: 155–63.
- Hayward R, Hydock DS. Doxorubicin cardiotoxicity in the rat: an in vivo characterization. *J Am Assoc Lab Anim Sci* 2007; 46: 20–32.
- Miyoshi T, Nakamura K, Amioka N, et al. LCZ696 ameliorates doxorubicin-induced cardiomyocyte toxicity in rats. *Sci Rep* 2022; 12: e4930. doi:10.1038/s41598-022-09094-z
- Bardi E, Bobok I, Olah AV, Kappelmayer J, Kiss C. Anthracycline antibiotics induce acute renal tubular toxicity in children with cancer. *Pathol Oncol Res* 2007; 13: 249–53.
- Kalender Y, Yel M, Kalender S. Doxorubicin hepatotoxicity and hepatic free radical metabolism in rats. The effects of vitamin E and catechin. *Toxicol* 2005; 209: 39–45.

23. Freiwan M, Kovacs MG, Kovacs ZZA, et al. Investigation of the anti-remodeling effects of losartan, mirabegron and their combination on the development of doxorubicin-induced chronic cardiotoxicity in a rat model. *Int J Mol Sci* 2022; 23: e2201. doi: 10.3390/ijms23042201
24. Medeiros-Lima DJM, Carvalho JJ, Tibirica E, Borges JP, Matsuura C. Time course of cardiomyopathy induced by doxorubicin in rats. *Pharmacol Rep* 2019; 71: 583–90.
25. Willis MS, Parry TL, Brown DI, et al. Doxorubicin exposure causes subacute cardiac atrophy dependent upon the striated muscle-specific ubiquitin ligase MuRF-1. *Circ Heart Fail* 2019; 12: e005234. doi: 10.1161/CIRCHEARTFAILURE.118.005234
26. Cantor EJ, Babick AP, VasANJI Z, Dhalla NS, Netticadan T. A comparative serial echocardiographic analysis of cardiac structure and function in rats subjected to pressure or volume overload. *J Mol Cell Cardiol* 2005; 38: 777–86.
27. Duler L, Visser LC, Jackson KN, Philips KL, Pollard RE, Wanamaker MW. Evaluation of radiographic predictors of left heart enlargement in dogs with known or suspected cardiovascular disease. *Vet Radiol Ultrasound* 2021; 62: 271–81.
28. Lam C, Gavaghan BJ, Meyers FE. Radiographic quantification of left atrial size in dogs with myxomatous mitral valve disease. *J Vet Intern Med* 2021; 35: 747–54.
29. Poad MH, Manzi TJ, Oyama MA, Gelzer AR. Utility of radiographic measurements to predict echocardiographic left heart enlargement in dogs with preclinical mitral valve disease. *J Vet Intern Med* 2020; 34: 1728–33.
30. Badea CT, Hedlund LW, Cook J, Berridge BR, Johnson GA. Micro-CT imaging assessment of dobutamine-induced cardiac stress in rats. *J Pharmacol Toxicol Methods* 2011; 63: 24–9.
31. Azar AD, Tavakoli F, Moladoust H, Zare A, Sadeghpour A. Echocardiographic evaluation of cardiac function in ischemic rats: value of m-mode echocardiography. *Res Cardiovasc Med* 2014; 3: e22941. doi: 10.5812/cardiovascmed.22941
32. Fries RC, Gordon SG, Saunders AB, Miller MW, Hariu CD, Schaeffer DJ. Quantitative assessment of two- and three-dimensional transthoracic and two-dimensional transesophageal echocardiography, computed tomography, and magnetic resonance imaging in normal canine hearts. *J Vet Cardiol* 2019; 21: 79–92.
33. Ederhy S, Mansencal N, Reant P, Piriou N, Barone-Rochette G. Role of multimodality imaging in the diagnosis and management of cardiomyopathies. *Arch Cardiovasc Dis* 2019; 112: 615–29.
34. Bagardi M, Manfredi M, Zani DD, Brambilla PG, Locatelli C. Interobserver variability of radiographic methods for the evaluation of left atrial size in dogs. *Vet Radiol Ultrasound* 2021; 62: 161–74.
35. Hansson K, Häggström J, Kvarn C, Lord P. Interobserver variability of vertebral heart size measurements in dogs with normal and enlarged hearts. *Vet Radiol Ultrasound* 2005; 46: 122–30.
36. Şirin YS, Çetinkaya MA, Kaya M. The evaluation of eccentric cardiac hypertrophy due to volume overload using radiographic cardiac indices in rats. *Thai J Vet Med* 2022; 52: 737–44.

Natančnost diagnostike radiografskih kazalcev srca pri ocenjevanju kardiomegalije in povečanja levega preddvora pri podganah z dilatativno kardiomiopatijo: Eksperimentalna študija

M. Kaya, M. A. Çetinkaya

Izvleček: Namen te študije je bil določiti diagnostično vrednost vertebralne srčne ocene (VHS), radiografske dimenzije levega atrija (RLAD) in vertebralne velikosti levega atrija (VLAS) pri radiografski oceni z doksorubicinom povzročene dilatativne kardiomiopatije (DCM) pri podganah. Živali so bile razdeljene v dve eksperimentalni skupini: skupino z DCM ($n=100$), ki je devet tednov prejela tedenske injekcije doksorubicina (2 mg/kg na odmerek intraperitonealno [ip]), in kontrolno skupino ($n=18$), ki je prejela ustrezno količino 0,9 % fiziološke raztopine ip. Radiografske kazalnike srca (VHS, RLAD, VLAS) smo izmerili dva tedna po zadnji injekciji, morfološke parametre srca (teža srca [HW], razmerje med težo srca in telesno težo [HBW] ter razmerje med težo srca in dolžino goleni [HTL]) pa smo določili po žrtvovanju vseh preživelih podgan (17 kontrolnih in 54 DCM). Izračunane so bile korelacije med kazalniki in parametri ter njihova občutljivost in specifičnost pri odkrivanju kardiomegalije in povečanja levega atrija (LAE) s tremi klasifikatorji ($HW \leq 0,96$ g, $HBW \leq 235$ in $HTL \leq 201$). Med kazalniki in parametri je bila ugotovljena močna negativna korelacija ($r_s \geq -0,711$, $P < 0,001$). Vrednosti površine pod krivuljo so bile 0,989 za RL-VHS, 0,992 za DV-VHS, 0,971 za RLAD in 0,948 za VLAS. Občutljivost in specifičnost teh kazalnikov pri odkrivanju kardiomegalije in LAE pri optimalnih mejnih vrednostih sta bili 94,4 % oziroma 100 % pri 8,8 vretencu (v) za RL-VHS in DV-VHS, 96,3 % oziroma 94,1 % pri 1,4 v za RLAD ter 94,4 % oziroma 88,2 % pri 2,1 v za VLAS. Radiografski kazalniki srca omogočajo natančno in ponovljivo metodo za napovedovanje kardiomegalije in LAE pri podganah z DCM.

Ključne besede: dilatativna kardiomiopatija; doksorubicin; VHS; RLAD; VLAS; podgana