

***Pentatrichomonas hominis* COINFECTION IN A PUPPY FROM A SLOVENIAN ANIMAL SHELTER**

Maja Brložnik¹, Siniša Faraguna², Brigita Slavec³, Rok Kostanjšek⁵, Aleksandra Vergles Rataj⁴, Igor Gruntar⁴

¹PRVA-K, Small Animal Clinic, Gorkičeva 6, Ljubljana, ²Veterinary faculty, ³Institute for Health Care of Poultry, ⁴Institute of Microbiology and Parasitology, Veterinary Faculty, Gerbičeva 60, Ljubljana, ⁵Department of Biology, Biotechnical Faculty, Jamnikarjeva 101, Ljubljana, Slovenia

*Corresponding author, E-mail: igor.gruntar@vf.uni-lj.si

Summary: A 3-month-old dog originating from a Slovenian animal shelter presented with acute bloody, soft, foamy and malodorous diarrhoea. The clinical examination, haematology and serum biochemistry were unremarkable. Ultrasonography of the abdomen showed prominent mesenteric lymph nodes and the presence of echogenic content within the small intestine. Light microscopy of a native smear and a wet mount darkfield microscopy examination of the faecal material showed motile trichomonad-like organisms with a particular circular motion. The flotation and SAF (Sodium acetate - acetic acid - formalin solution) method using light microscopy revealed eggs of nematode *Toxocara canis* and protozoan oocysts of *Isospora* spp. Trichomonad-like organisms were successfully isolated and cultivated in axenic culture. Light microscopy of Giemsa-stained trichomonads showed the presence of five flagella, and *Pentatrichomonas hominis* (*P. hominis*) was presumptively diagnosed. The diagnosis was confirmed by the Polymerase Chain Reaction (PCR) followed by DNA sequencing and the Scanning Electron Microscopy (SEM) of cultured trichomonad isolates. The PCR and sequencing results confirmed a 99% homology of the *P. hominis* isolates with isolates from other studies, originating both from humans and animals, which suggests that *P. hominis* could have zoonotic potential and have been transmitted from animals to people via the per-oral route. This is also the first report on *P. hominis* involvement in clinical diseases in dogs in Slovenia.

Key words: *Pentatrichomonas hominis*; dog; isolation; cultivation; PCR; DNA sequencing; scanning electron microscopy

Introduction

Young dogs are commonly infested with different zoonotic intestinal parasites. Conventional canine intestinal parasites of zoonotic importance, such as *Toxocara*, *Taenia*, *Ancylostoma*, *Giardia*, *Cryptosporidium*, etc., have been studied thoroughly, but less is known about the zoonotic trichomonad species *Pentatrichomonas hominis* (*P. hominis*), formerly *Trichomonas intestinalis*

or *Trichomonas hominis* (1). This flagellated protozoan has recently been identified in faeces of dogs with diarrhoea (2, 3, 4, 5). The pathogenicity of the parasite remains unclear. Due to the lack of evidence of cases where *P. hominis* was the only infecting agent, this trichomonad is presumed to be a commensal organism that may overgrow in patients with other causes of diarrhoea. As enteropathogens have always been found in dogs infected by *P. hominis* (6), the pathogenic potential of this trichomonad species has to be further evaluated by experimental infection studies (4). For such trials an axenic *P. hominis* culture of

dog origin is needed, which, to the best of our knowledge, has not yet been available. In humans, *P. hominis* has been reported as the causative agent of gastrointestinal disturbances in children (7, 8, 9). Therefore the assessment of the zoonotic potential of canine *P. hominis* is important. It is also necessary to establish whether host-specific genotypes exist as demonstrated among *Tritrichomonas foetus* isolates from cats and cattle (10, 11). To prove this, the characterisation of as many isolates as possible from diverse hosts should be performed. A study carried out last year (12), however, demonstrates that even when using the high-resolution gene locus of the ITS (internal transcribed spacer) regions, all *P. hominis* strains from diverse hosts are genetically identical. This suggests that zoonotic transmission between humans and animals may occur in the area investigated. Consequently, further research is required to clarify the role of *P. hominis* in human and animal diseases. This article provides the first description of *P. hominis* involved in a clinical disease in dogs in Slovenia. The trichomonad was successfully isolated and cultivated in axenic culture. The presumptive diagnosis based on light microscopy was confirmed by SEM and PCR.

Material and methods

Case Description and Sampling

A 3-month old, 9 kg mixed breed and regularly vaccinated dog that had recently been adopted from a Slovenian shelter, presented at a small animal clinic with acute bloody, soft, foamy and malodorous diarrhoea. Clinical examination, haematology, blood serum biochemistry and abdominal ultrasonography were performed. According to the results viral etiology was ruled out. Consequently, coprological and bacteriological analyses of a faecal sample were carried out. The faecal sample was analysed using light microscopy, bacteriological examination, flotation, sedimentation and the SAF (Sodium acetate-acetic acid-formalin solution) method. Bacteriological analyses of faecal samples were conducted on blood agar and Drigalski agar plates, incubated aerobically and anaerobically at 37 °C overnight. The isolation of trichomonads followed. SEM and PCR were used for definitive diagnosis.

Isolation of Trichomonads

Trichomonads were isolated using the following procedure: a set of 3 tubes containing Modified Diamond's growth medium (MDM) was inoculated with a loopful (approx. 0.1 g) of faecal sample and incubated at 37°C for seven days (13). In parallel, another set of tubes was inoculated in the same way, this time with MDM supplemented with meropenem (6 µg/ml; MeMDM), to provide additional prevention against bacterial contamination (14). The inoculated tubes were checked for trichomonad growth at intervals during this period. An aliquot was taken from the bottom of the tube and wet mount-examined by darkfield microscopy. When motile flagellates were observed, an aliquot (0.1 ml) of fresh culture was transferred to fresh MDMs/MeMDMs.

Staining of Isolated Trichomonads

Thin smears of cultivated trichomonad suspension were air-dried, fixed and stained with Giemsa, trichrome and methylene blue stain.

Scanning Electron Microscopy

For scanning electron microscopy, the trichomonads in the cultivation suspension were washed with phosphate buffered saline (PBS) by centrifugation at 100 xg for 5 min before overnight fixation in a combination of 1 % glutaraldehyde and 0.5 % paraformaldehyde in 0.1 M phosphate buffer (pH 7.4) at 4 °C. Fixed cells were transferred to pre-cleaned cover slides, washed by PBS and postfixed in 2 % OsO₄ for one hour at 4 °C. After being washed in deionized water, the cells on the slides were dehydrated in a graded series of ethanols, then dried by hexamethyldisilazane (HMDS), mounted on aluminum stubs and coated with platinum, as described above (15). The samples were examined with the JEOL JSM-7500F field emission scanning electron microscope.

Molecular Diagnosis

For the molecular detection of trichomonads, two hundred microlitres of protozoal culture suspension were used. Total DNA was extracted using the QIAamp® Mini Kit (Qiagen, Hilden, Germany), according to the manufacturer's instructions for

blood and body fluid spin protocol. Finally, the DNA was eluted with 100 µl of AE buffer and stored at -20 °C until examination. Specific pairs of primers TFR1 and TFR2 amplifying the 350 bp long ITS1-5.8S-ITS2 region were used (16). PCR was performed in a total volume of 20 µl containing 10 µl of 2X Thermo Scientific DreamTaq Green PCR Master Mix (Thermo Fisher Scientific, CA, USA), 0.8 µl of each primer (0.4 µM), 6.4 µl of nuclease-free water and 2 µl of extracted DNA. The reaction was performed on an ABI 2720 Thermo Cycler (Applied Biosystems, Foster City, CA, USA). The cycling profile included initial denaturation at 95 °C for 5 min, which was followed by 40 cycles of heat denaturation at 94 °C for 30 sec, oligonucleotide annealing at 55 °C for 1 min, oligonucleotide extension at 72 °C for 1 min, and final oligonucleotide extension step at 72 °C for 10 min. The extracted DNA of *Trichomonas gallinae* was used as positive control in the PCR assay.

The PCR products were analysed by electrophoresis on a 1.8 % ethidium bromide-stained agarose gel. DNA fragments were excised from the gel and, after being purified with the Wizard PCR Preps DNA Purification System (Promega, Madison, WI, USA), sent for sequencing to the Macrogen laboratory (Macrogen Inc, Amsterdam, the Netherlands).

The nucleotide sequences were downloaded using Chromas software (Technelysium Pty Ltd., Queensland, Australia), and the nucleotide

sequence data were analysed by BLAST (17) to find similar sequences in the Genbank NCBI sequence database.

Results

The clinical examination of the diarrhoeic 3-month old mixed breed dog was unremarkable. Haematology and serum biochemistry did not reveal any abnormalities. Ultrasonography of the abdomen showed prominent mesenteric lymph nodes and the presence of echogenic content within the small intestine.

Light microscopy of the native faecal smear and darkfield microscopy (wet mount examination) of the diarrhoeic material showed numerous motile trichomonad-like organisms with a particular circular motion. Flotation and the SAF method using light microscopy revealed *Toxocara canis* nematode eggs (Figure 1), *Isospora* sp. oocysts (Figure 2) and the above-mentioned trichomonad species. Bacteriological analyses of faecal samples were negative for aerobic and anaerobic pathogens. Trichomonad isolation and cultivation attempts were successful. Numerous motile trichomonads were observed after seven days incubation in MDM (xenic culture; with other organisms - bacteria - present). In MeMDM, the trichomonads were less abundant but other organisms were absent (axenic culture). The cultures were stored

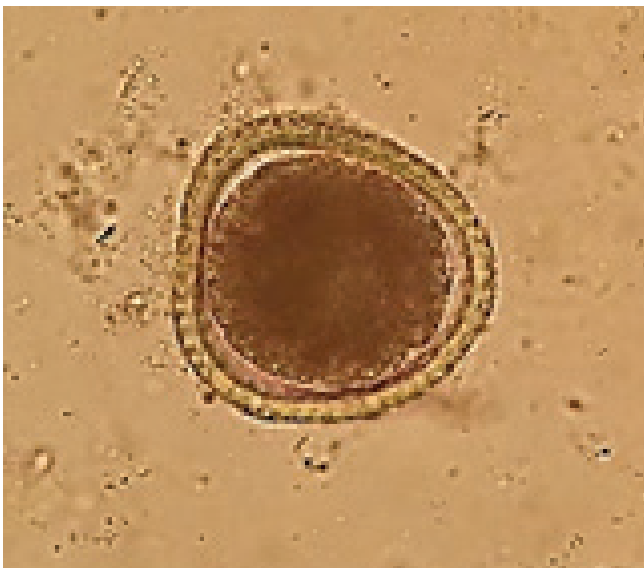

Figure 1: *Toxocara canis* egg, size 90 x 80 µm, flotation method, x400

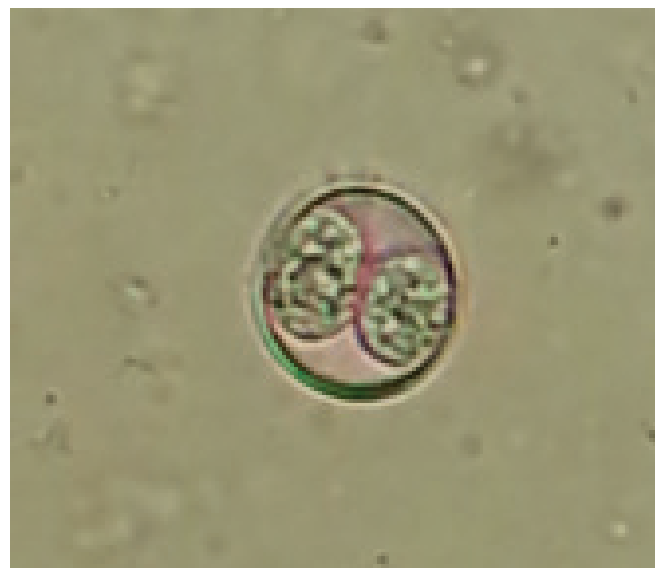

Figure 2: *Isospora* sp. oocyst, size 23 x 18 µm, flotation method, x400

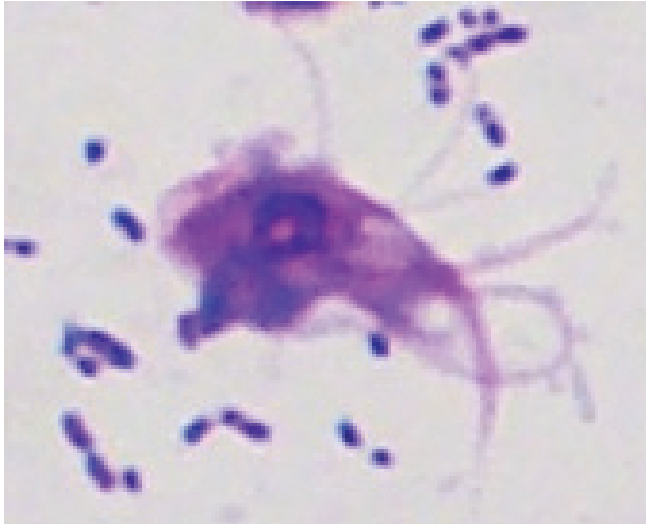

Figure 3: *Pentatrichomonas hominis* trophozoite, Giemsa, x1000

using 10 % dimethylsulphoxide (18). The isolated trichomonads were stained with Giemsa, trichrome and methylene blue stain. When examined by light microscopy, the Giemsa stain improved the visibility and enabled the enumeration of flagella (Figure 3).

The SEM and PCR assay confirmed the diagnosis of *P. hominis*. SEM observations revealed the presence of five flagella in the anterior part of the trichomonad (four flagella in a group and a single independent flagellum) and one in the posterior part (Figure 4). The latter run from the anterior part, alongside the cell in a posterior direction, forming a distinct undulating membrane displaying three undulations. It ended freely at its distal end. The axostyle was observed as a discrete tip in the posterior region of the cell.

With PCR and sequencing, a high similarity of obtained sequence (Accession No. KU670675) with *P. hominis* was confirmed. The comparison of the 300 bp long sequence of the complete ITS1-5.8S-ITS2 gene had 100 % homology with *P. hominis* isolate from empyema thoracis (Accession No. AF156964), and 99 % homologies with the *P. hominis* isolates from a human (Acc. No. JN007007) and a dog (Acc. No. KJ404270).

The dog was treated with metronidazole 200 mg/12 h p/o for 5 days and Dehinel plus® (febantel 150 mg, pyrantel embonate 144 mg, praziquantel 50 mg) 1 tbl/day for 5 days. The dog's condition improved immediately, and the faecal exam was negative two weeks after the treatment. Since then, the dog has been asymptomatic for one year.

Discussion

P. hominis, a flagellated protozoan of the order *Trichomonadida*, inhabits the large intestine of many mammalian hosts, including humans (6, 7, 8, 9, 19). Its prevalence in humans is low in developed countries (20), but is much higher in subtropical and tropical zones (21). In dogs, the prevalence of the trichomonad infection in a study analysing 215 puppies from French kennels was 15.8% (4). This study also reports that *P. hominis* was the only trichomonad infecting the studied canine population, whereas some older papers suggest that *P. hominis* was far more frequent than *Tritrichomonas foetus* in diarrhoeic dogs suffering from trichomonosis (2, 3, 6).

In the majority of studies (2, 3, 4), the reported age of dogs with trichomonosis ranged from 7 weeks to 6 months which is consistent with the age of the 3-month-old dog in this case. A more recent study reported that trichomonosis was also diagnosed in 10-year-old dogs (6).

Differential diagnoses for bloody, soft, foamy and malodorous diarrhoea are dietary intolerance, infection, partial obstruction, motility disorders, inflammatory/immune-mediated disease, drugs/toxins, idiopathic disease, neoplasia and extra-gastrointestinal disease (22). Given the age of the dog in this study, the clinical signs and results of the clinical investigation, infection was considered the most likely cause. Considering that the dog has been routinely vaccinated against viral diseases, the absence of leukopenia in haematology results, as well as lack of other usual clinical signs, parvoviral enteritis was not suspected and additional diagnostics regarding shedding the parvoviruses was not performed. The excretion of other viruses is generally not evaluated in practice, since viral diarrhoea is usually self-limiting and does not require a positive diagnosis. The negative results of the bacteriological analyses led to the conclusion that the mixed trichomonad-parasitic-coccidial infection was responsible for the symptoms. However, it is difficult to presume about the origin of the diarrhea from amongst the three organisms. It is most likely that the concurrency of the pathogens was significant.

Microscopical observations of unusual and copious trichomonad-like organisms in the native sample was a surprising finding, which triggered additional efforts to characterise these organisms. Microscopy cannot be used to identify the




Figure 4: *Pentatrichomonas hominis* trophozoite, A – anterior flagella, B – posterior flagellum, C – undulating membrane, D – axostyle, E – independent flagellum, SEM x 550

trichomonad species in native samples (23, 24, 25). Flagella are not well discernible in such preparations, but their visibility improves with the use of stains, thus supporting the species differentiation.

Trichomonad species can accurately be determined by SEM: for the purposes of this study the isolate was characterised as a pear-shaped organism with distinctive undulating membrane, an axostyle, a single posterior (recurrent) flagellum and five anterior flagella, comprising a group of four flagella of unequal length and a single independent flagellum. The undulating membrane displayed three undulations. An axostyle was an elongated rod-like structure projecting out of the posterior end to form a pointed spine. The axostyle is an important criterion for distinguishing tritrichomonads from pentatrichomonads (5, 26). In this study, the axostyle of the trichomonad had a relatively heavy terminal segment and was observed as a discrete tip in the posterior region of the cell. By contrast, the axostyle of the *T. foetus* has a short conical projection with a small spherical structure at the end (27). Furthermore, it has only 3 anterior flagella. The long undulating membrane is also suggestive of *P. hominis* because the other trichomonads have a shorter undulating membrane (27).

For the detection of *P. hominis* in biological specimens, a highly specific and sensitive PCR assay can be used (28, 29, 30). In this case, the PCR assay for amplification of the 5.8S rRNA gene and two flanking internal transcribed spacer

regions ITS1 and ITS2 of trichomonads was used. This region is one of the most used for taxonomic classification of trichomonads (16). The results confirmed high homology of this isolate with the previously described genetic loci of *P. hominis* from various mammalian hosts (humans, dogs, cattle, pigs, cats, goats, water buffaloes), suggesting a low genetic diversity in *P. hominis* isolates and a very broad host range for this species (5, 12, 28, 29, 30).

Therefore, it is possible that *P. hominis* strains may circulate between different hosts, including humans, where they, under certain circumstances, may cause clinical disease (7, 8, 9) or exacerbate symptoms of an existing illness (31). To elucidate the actual role and pathogenicity of *P. hominis* in human and animal disease, further research is needed.

Conclusion

Routine coprological examinations, at least microscopic evaluation of the stool for protozoans, parasites and the ova (eggs, cysts) of parasites, are essential for a correct diagnosis in a dog with diarrhoea. In the case of trichomonads, SEM or PCR assays are required for the definite diagnosis of trichomonad species. Molecular diagnostic data of trichomonads suggest that *P. hominis* is a zoonotic species with the potential for transmission via the per-oral route from animals to people and vice-versa.

References

1. Pentatrachomonas. In: Studdert VP, Blood DC, Gay CC, eds. Saunders comprehensive veterinary dictionary. 4th ed. Edinburgh ; New York : Elsevier Saunders, 2012: 831.
2. Gookin JL, Stauffer SH, Coccaro MR, Marcotte MJ, Levy MG. Optimization of a species-specific polymerase chain reaction assay for identification of *Pentatrachomonas hominis* in canine fecal specimens. *Am J Vet Res* 2007; 68: 783–7.
3. Kim YA, Kim HY, Cho SH, Cheun HI, Yu JR, Lee SE. PCR detection and molecular characterization of *Pentatrachomonas hominis* from feces of dogs with diarrhea in the Republic of Korea. *Korean J Parasitol* 2010; 48: 9–13.
4. Grellet A, Polack B, Feugier A, et al. Prevalence, risk factors of infection and molecular characterization of trichomonads in puppies from French breeding kennels. *Vet Parasitol* 2013; 197: 418–26.
5. Li WC, Gong PT, Ying M, Li JH, et al. *Pentatrachomonas hominis*: first isolation from the feces of a dog with diarrhea in China. *Parasitol Res* 2014; 113: 1795–1801.
6. Tolbert MK, Leutenegger CM, Lobetti R, Birrell J, Gookin JL. Species identification of trichomonads and associated coinfections in dogs with diarrhea and suspected trichomonosis. *Vet Parasitol* 2012; 187: 319–22.
7. Yang CR, Meng ZD, Wang X, Li YL, Zhang YX, Zhao QP. Diarrhoea surveillance in children aged under 5 years in a rural area of Hebei Province, China. *J Diarrhoeal Dis Res* 1990; 8: 155–9.
8. Chung RN, Nagelkerke N, Karumba PN, et al. Longitudinal study of young children in Kenya: intestinal parasitic infection with special reference to *Giardia lamblia*, its prevalence, incidence and duration, and its association with diarrhoea and with other parasites. *Acta Trop* 1991; 50: 39–49.
9. Meloni D, Mantini C, Goustille J, et al. Molecular identification of *Pentatrachomonas hominis* in two patients with gastrointestinal symptoms. *J Clin Pathol* 2011; 64: 933–5.
10. Šlapeta J, Craig S, McDonnell D, Emery D. *Tritrachomonas foetus* from domestic cats and cattle are genetically distinct. *Exp Parasitol* 2010; 126: 209–13.
11. Reinmann K, Müller N, Kuhnert P, et al. *Tritrachimonas foetus* isolates from cats and cattle show minor genetic differences in unrelated loci ITS-2 and EF-1 α . *Vet Parasitol* 2012; 185: 138–44.
12. Kamaruddin M, Tokoro M, Rahman M, et al. Molecular characterization of various trichomonad species isolated from humans and related mammals in Indonesia. *Korean J Parasitol* 2014; 52: 471–8.
13. Trichomonosis. In: OIE Manual of diagnostic tests and vaccines for terrestrial animals. 7th ed. [Online]. Paris: The World Organization of Animal Health, 2012: chapter 2.4.17 (8 pp.) (adopted ver. May 2012) http://www.oie.int/fileadmin/Home/eng/Health_standards/tahm/2008/pdf/2.04.17_TRICHOMONOSIS.pdf (14. 10. 2015)
14. Amin A, Neubauer C, Liebhart D, Grabensteiner E, Hess M. Axenization and optimization of in vitro growth of clonal cultures of *Tetratrachomonas gallinarum* and *Trichomonas gallinae*. *Exp Parasitol* 2010; 124: 202–8.
15. Kostanjšek R, Pirc-Marolt T. Pathogenesis, tissue distribution and host response to *Rhabdochlamydia porcellionis* infection in rough woodlouse *Porcellio scaber*. *J Invertebr Pathol* 2015; 125: 56–67.
16. Felleisen RS. Comparative sequence analysis of 5.8S rRNA genes and internal transcribed spacer (ITS) regions of trichomonadid protozoa. *Parasitology* 1997; 115: 111–9.
17. Altschul SF, Gish W, Miller W, Myers EW, Lipman DJ. Basic local alignment search tool. *J Mol Biol* 1990; 215: 403–10.
18. Miyake Y, Karanis P, Uga S. Cryopreservation of protozoan parasites. *Cryobiology* 2004; 48: 1–7.
19. Gookin JL, Stauffer SH, Levy MG. Identification of *Pentatrachomonas hominis* in feline fecal samples by polymerase chain reaction assay. *Vet Parasitol* 2007; 145: 11–5.
20. Ackers JP. Trichomonads. In: Gillespie SH, Pearson RD, eds. Principles and practice of clinical parasitology. Chichester: John Wiley & Sons, 2001: 258–60.
21. Saksirisampant W, Nuchprayoon S, Witanitkit V, Yenthakam S, Ampavasiri A. Intestinal parasitic infestations among children in an orphanage in Pathum Thani province. *J Med Assoc Thai* 2003; 86: 263–70.
22. Gough A. Differential diagnosis in small animal medicine. Oxford: Blackwell, 2007: 26–31.
23. Romatowski J. *Pentatrachomonas hominis* infection in four kittens. *J Am Vet Med Assoc* 2000; 216: 1270–2.
24. Gookin JL. Trichomoniasis. In: Greene

CE, ed. Infectious diseases of the dog and cat. 4th ed. St. Louis: Saunders, 2012: 797–801.

25. Rivera WL, Lupisan AJ, Baking JM. Ultrastructural study of a tetratrachomonad isolated from pig fecal samples. *Parasitol Res* 2008; 103: 1311–6.

26. Levy MG, Gookin JL, Poore M, Birkenheuer AJ, Dykstra MJ, Litaker RW. *Tritrichomonas foetus* and not *Pentatrachomonas hominis* is the etiologic agent of feline trichomonal diarrhea. *J Parasitol* 2003; 89: 99–104.

27. Warton A, Honigberg BM. Structure of trichomonads as revealed by scanning electron microscopy. *J Protozool* 1979; 26: 56–62.

28. Crucitti T, Abdellati S, Ross DA, Changalucha J, van Dyck E, Buve A. Detection of *Pentatri-*

chomonas hominis DNA in biological specimens by PCR. *Lett Appl Microbiol* 2004; 38: 510–6.

29. Gookin JL, Birkenheuer AJ, St John V, Spector M, Levy MG. Molecular characterization of trichomonads from feces of dogs with diarrhea. *J Parasitol* 2005; 91: 939–43.

30. Mostegl MM, Wetscher A, Richter B, Nedorost N, Dinhopl N, Weissenböck H. Detection of *Tritrichomonas foetus* and *Pentatrachomonas hominis* in intestinal tissue specimens of cats by chromogenic in situ hybridization. *Vet Parasitol* 2012; 183: 209–14.

31. Jongwutiwes S, Silachamroon U, Putaporn-tip C. *Pentatrachomonas hominis* in empyema thoracis. *Trans R Soc Trop Med Hyg* 2000; 94: 185–6.

SOOKUŽBA S PROTOZOJEM *Pentatrachomonas hominis* PRI PSU IZ SLOVENSKEGA ZAVETIŠČA

M. Brložnik, S. Faraguna, B. Slavec, R. Kostanjšek, A. Vergles Rataj, I. Gruntar

Povzetek: Na kliniko smo zaradi akutne krvave, penaste in smrdljive driske sprejeli tri mesece starega psa, ki so ga lastniki nedavno posvojili iz zavetišča. Klinični pregled ter hematološke in biokemične preiskave krvi so bili brez posebnosti. Pri pregledu trebuha z ultrazvokom smo ugotovili velike mezenterialne bezgavke, tanko črevo pa je bilo polno ehogene vsebine. Z mikroskopskim pregledom nativnih preparatov smo v vzorcu blata opazili številne gibljive organizme, podobne trihomonasom, s specifičnim krožnim gibanjem. Z mikroskopiranjem ter s flotacijo in metodo SAF smo diagnosticirali še jajčeca nematodov *Toxocara canis* in oociste praživali *Isospora sp.* Trihomonasom podobne organizme smo uspešno izolirali in jih vzgojili v čisti kulturi. Mikroskopski pregled organizmov, obarvanih po Giemsi, je omogočil določitev števila bičkov in vzpostavitev suma na okužbo s *Pentatrachomonas hominis* (*P. hominis*). Diagnozo smo dokončno potrdili s polimerazno verižno reakcijo (PCR) in določitvijo baznega zaporedja, ter z vrstičnim elektronskim mikroskopom. PCR in določitev baznega zaporedja sta pokazala 99 % skladnost našega izolata z izolati *P. hominis* iz drugih gostiteljev/študij. Ta podatek kaže na zoonotski potencial *P. hominis* in na možnost peroralnega prenosa med živalmi in ljudmi. Članek predstavlja tudi prvo poročilo o trihomonadni okužbi s *P. hominis* pri psih v Sloveniji.

Ključne besede: *Pentatrachomonas hominis*; pes; izolacija; gojenje; PCR; določanje zaporedja DNK; vrstična elektronska mikroskopija