

## ***Brevundimonas vesicularis* SEPTICAEMIA IN A KID WITH CONGENITAL GOITRE**

Mitja Gombač<sup>1\*</sup>, Igor Gruntar<sup>2</sup>, Pavel Kvapil<sup>3</sup>, Tanja Švara<sup>1</sup>

<sup>1</sup>Institute of Pathology, Wild animals, Fish and Bees, Veterinary Faculty, <sup>2</sup>Institute of Microbiology and Parasitology, Veterinary Faculty, University of Ljubljana, Gerbičeva 60, <sup>3</sup>ZOO Ljubljana, Večna pot 70, 1000 Ljubljana, Slovenija

\*Corresponding author, E-mail: mitja.gombac@vf.uni-lj.si

**Summary:** In this article a case of septicaemia, caused by *Brevundimonas vesicularis* in a newborn pygmy goat with congenital goitre, is described. *B. vesicularis* is an aerobic non-sporulating non-fermenting motile Gram-negative bacillus, ubiquitous in the environment. It is susceptible to aminoglycosides and anti-pseudomonal penicillins and resistant to ampicillin and cephalosporins. To date, *B. vesicularis* has been isolated from water, soil, plants and several human clinical specimens, mostly in immunosuppressed patients causing endocarditis, arthritis, keratitis and septicaemia. It has never been reported to cause any problems in animals.

A newborn pygmy goat kid died 18 hours after a normal parturition. Prior to death, no clinical abnormalities were observed, the kid was normally developed, in good condition and had a normal suckling reflex. At necropsy, a severely enlarged thyroid gland, an acute embolic pneumonia, acute catarrhal enteritis and a moderate splenomegaly were noticed. Microscopically, severe thyroid gland hyperplasia, embolic pneumonia and catarrhal enteritis were confirmed. In the liver and myocardium small multifocal necroses, surrounded by single neutrophils, were noticed. A severe diffuse lymphoreticular hyperplasia was diagnosed in the spleen and a diffuse parenchymatous degeneration was noticed in the kidneys. Numerous small colonies of Gram-negative bacteria were observed in the liver and lungs. Intensive growth of smooth, thick, convex, yellowish colonies on blood agar and green colonies on Drigalski agar was obtained from the liver, spleen and lung samples. The bacteria were identified as *B. vesicularis* by a commercial kit. The bacterium resulted sensitive to broad-spectrum antimicrobial agents, including ampicillin, cefotaxime, ceftriaxone and ceftazidime-clavulanate.

To the best of our knowledge, this is the first report of *B. vesicularis* septicaemia in animals. Weak immunodeficient goitrous kids are predisposed to many bacterial infections, including the ubiquitous and opportunistic *B. vesicularis*, which can cause fulminant septicaemia and death within a few hours after birth.

**Key words:** *Brevundimonas vesicularis*; congenital goitre; newborn kid; pneumonia; septicaemia

### **Introduction**

*Brevundimonas vesicularis* is an aerobic non-sporulating, non-fermenting, motile Gram-negative bacillus, ubiquitous in the environment (1,2,3). It was first isolated from a leech in 1954 and classified as a member of group IV of the genus *Pseudomonas* and named *Pseudomonas vesicularis* (1). In 1994 it was reclassified in the genus *Brevundimonas* (4). In humans, *B. vesicularis*

has been isolated from blood, cerebrospinal fluid, urine, eye, wound and vaginal cultures (1), but was only occasionally implicated in human infections, mostly in immunocompromised patients (1,5-8), making it an opportunistic bacterium. It has never been reported to cause any problems in animals. To the best of our knowledge, this is the first report of septicaemia caused by *B. vesicularis* in animals.

### **Materials and methods**

The pygmy goat kid was dissected at the Institute of Pathology, Wild animals, Fish and

Bees of the Veterinary Faculty, University of Ljubljana immediately after death.

Representative specimens of the thyroid gland, spleen, liver, small intestine, lungs, heart and kidneys were fixed in 10% neutral buffered formalin for 24 hours, routinely embedded in paraffin, sectioned at 4 µm and stained with hematoxylin and eosin (HE) and Gram. Samples of the spleen, liver, small intestine, lungs, heart and kidneys were taken for bacteriological examination. The standard bacteriological procedure for isolation of aerobic bacteria was used. Briefly, the samples were plated on blood and Drigalski agar plates and incubated for 24 h at 37°C under aerobic conditions. The isolate was tested for antimicrobial susceptibility using the disk diffusion method on Muller Hinton agar (Oxoid). Incubation time was 24 h at 37°C. The following antimicrobial agents were tested, using antibiotic discs (Becton Dickinson): amikacin (30 µg), piperacillin (30 µg), Cefotaxime (30 µg), Ceftriaxone (30 µg), Ceftazidime - calavulanate (30 µg), Gentamicin (15 µg), Imipenem (5 µg), Aztreonam (15 µg), Ciprofloxacin (30 µg), Polymyxin B (30 µg), Colistin (30 µg), Sulfamethoxazole-trimetoprim (30 µg), Amoxicillin-clavulanate (30 µg), Erythromycin (30 µg), Azithromycin (30 µg), and Tetracycline (30 µg). The strain was classified as resistant, intermediate or susceptible to antimicrobials tested according to NLSI breakpoints used for *Pseudomonas* sp., as proposed by Karadag et al. (9).

## Results

### History

A newborn, apparently healthy female pygmy goat kid from the Ljubljana Zoo, of normal birth weight (1.3 kg) died suddenly 18 hours after a normal parturition of twins. At the time of death a prominent enlargement in the throat region was observed. The gestation was normal and both doe and the other kid were healthy.

### Necropsy

The kid was normally developed and in good condition. No alterations were noticed in the umbilicus, and the umbilical vessels were normally obliterated. Abomasum was filled with 0.5 dl of partially clotted milk and in the initial

part of the small intestine there was a moderate amount of dense milky fluid. The thyroid gland was severely enlarged with each lobe measuring 4 cm x 2.5 cm x 1.5 cm (Figure 1). An acute embolic pneumonia with multifocal sub-pleural petechial haemorrhages, diffuse acute catarrhal enteritis, a moderate splenomegaly and mild liver, heart and kidney congestion were also observed. No changes were observed in other organs and tissues.

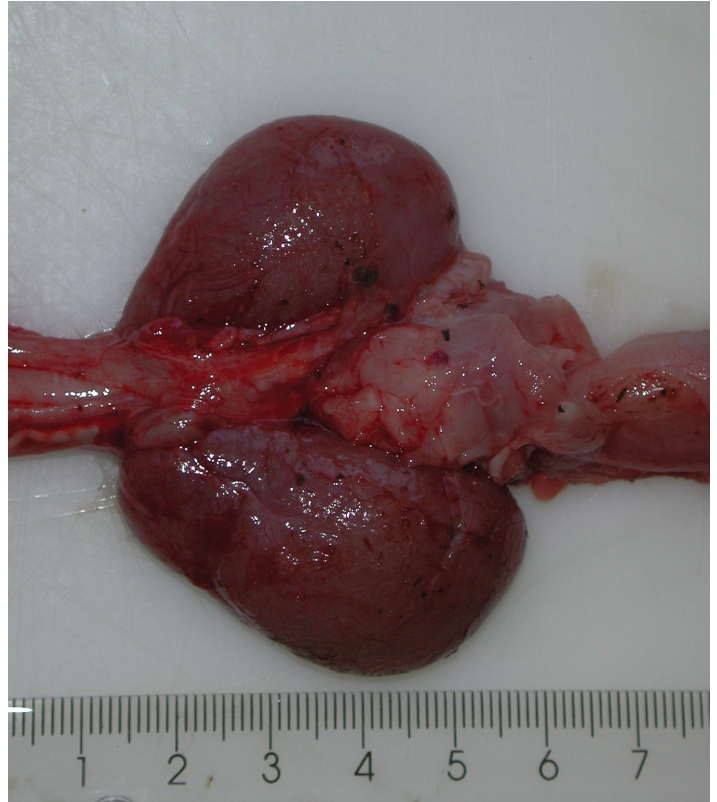
### Histopathology

Microscopically, a severe hyperplasia of the thyroid gland was diagnosed: the tissue consisted of numerous solid clusters and enlarged follicles filled with pale colloid and lined by flat or prismatic epithelium; multifocally, papillary processes protruded into the follicular lumina. The pulmonary alveoli were multifocally densely infiltrated with neutrophils and some alveolar macrophages (Figure 2). Small, scattered colonies of Gram-negative bacteria were observed in the alveoli. In the liver, random multifocal necroses with numerous colonies of Gram-negative bacteria in their centre were observed. At the periphery of the necrotic area, single neutrophils were noticed. Large bacterial colonies were also seen in the hepatic blood vessels. Small multifocal necroses with small groups of neutrophils and macrophages were observed in the myocardium. Acute diffuse catarrhal desquamative enteritis, severe diffuse lymphoreticular hyperplasia with severe hyperaemia of the spleen and diffuse parenchymatous degeneration of the kidneys were also observed.

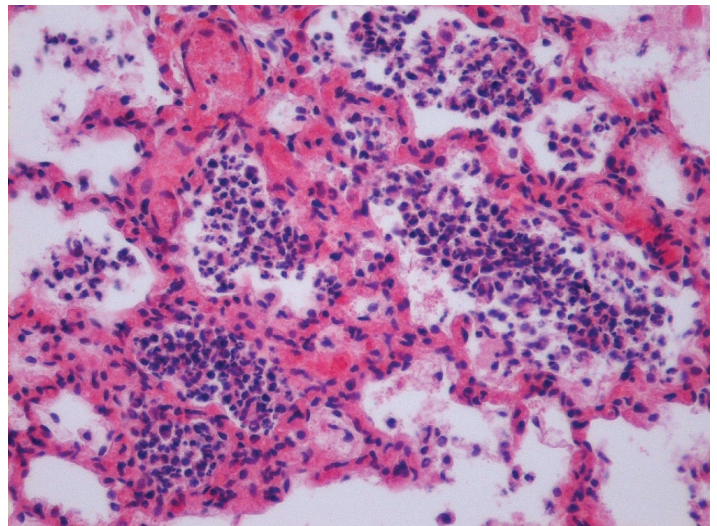
### Bacteriological culture

Intensive growth of smooth, thick, convex, yellowish colonies on blood agar and green colonies on Drigalski agar was obtained from the liver, spleen and lung samples. Gram staining revealed Gram-negative bacilli. Rapid oxidase test was positive and rapid indole test was negative. The bacteria were identified as *Brevundimonas vesicularis* by commercial kit (BBL Crystal Enteric/Nonfermenter ID Kit, Becton Dickinson). *Enterobacter cloacae* was detected on small intestine plates. Kidney sample plates remained sterile.

*B. vesicularis* resulted susceptible to all the tested antibiotics.



**Figure 1:** Necropsy finding. Severely enlarged thyroid gland



**Figure 2:** Embolic pneumonia. Note the pulmonary alveoli densely infiltrated with neutrophils and some alveolar macrophages. Hematoxylin and eosin, x 200

## Discussion

In the first few hours after birth a kid is susceptible to a number of specific infective pathogens and other infectious agents, normally considered to have low virulence, but can also cause disease if the immunological status of the neonate is not at an optimal level (10). Goitrous kids are

usually stillborn, or are born weak (11) and usually die within a few hours after birth (11,12) due to respiratory problems or increased susceptibility to stress and infection, mainly caused by *Escherichia coli*, *Clostridium perfringens* type B, *Staphylococcus aureus*, *Streptococcus* spp., *Corynebacterium* spp. or *Salmonella*, and often resulting in septicaemia (12,13). The increased susceptibility to infection is

linked to altered status of thyroid hormones, which affect natural killer cell activity and cell-mediated immune response, making goitrous patients immunocompromised (14). Albeit gestation of goitrous kids is significantly prolonged and dystocia and retained foetal placenta are often reported (11), this was not the case in our kid. The doe and the other twin were (and still are) clinically healthy. The kid later diagnosed with congenital goitre also showed no clinical disorders, but we believe it was immunocompromised and had died due to *B. vesicularis* septicaemia - *B. vesicularis* was isolated from the lungs, liver and spleen. Small colonies of Gram-negative bacteria were microscopically observed in inflamed pulmonary alveoli, hepatic blood vessels and in hepatic necroses.

*B. vesicularis* is a ubiquitous environmental microorganism that has been isolated from water, soil, plants and several human clinical specimens (1,6). Infection has so far only been described in humans, mostly in immunosuppressed patients suffering from leukaemia (1), sickle cell anaemia (8), biliary pancreatitis (5) or after surgical procedures (7,15). *B. vesicularis* was the cause of endocarditis (3), arthritis (2), keratitis (15), urinary tract infection (16), liver abscess (17) and bacteraemia/ septicaemia (1,5-8,18). Most of the infected patients recovered completely after adequate antibiotic therapy (2,3,5-7,15-17). *B. vesicularis* is uniformly susceptible to aminoglycosides and anti-pseudomonal penicillins and resistant to ampicillin and cephalosporins (7). In our case, the bacterium was sensitive to broad-spectrum antimicrobial agents, including ampicillin, cefotaxime, ceftriaxone and ceftazidime-clavulanate.

To the best of our knowledge, this is the first report of *B. vesicularis* septicaemia with microscopically described changes in organs in a kid with congenital goitre. Weak immunodeficient goitrous kids are predisposed to many bacterial infections, including the ubiquitous and opportunistic *B. vesicularis*, which can cause fulminant septicaemia and death within few hours after birth.

In conclusion, *B. vesicularis* may be an emerging pathogen in immunosuppressed animals and also in neonatal infections in animals.

## Acknowledgements

The authors gratefully acknowledge the Ljubljana ZOO for their permission to publish these data.

## References

1. Bobbak V. *Brevundimonas vesicularis* bacteremia following allogeneic bone marrow transplantation. *Internet J Infect Dis* 2005; 5: e1 (4 pp.) <http://print.ispub.com/api/0/ispub-article/9653> (12. 9. 2016)
2. Sofer Y, Zmira S, Amir J. *Brevundimonas vesicularis* septic arthritis in an immunocompetent child. *Europ J Pediatr* 2007; 166: 77-8.
3. Yang ML, Chen YH, Chen TC, Lin WR, Lin CY, Lu PL. Case report: infective endocarditis caused by *Brevundimonas vesicularis*. *BMC Infec Dis* 2006; 6: e179 (5 pp.) <http://link.springer.com/article/10.1186%2F1471-2334-6-179> (12. 9. 2016)
4. Segers P, Vancanneyt M, Pot B, et al. Classification of *Pseudomonas diminuta* Leifson and Hugh 1954 and *Pseudomonas vesicularis* Büsing, Döll, and Freytag 1953 in *Brevundimonas* gen. nov. as *Brevundimonas diminuta* comb. nov. and *Brevundimonas vesicularis* comb. nov., respectively. *Int J Syst Bact* 1994; 44: 499-510.
5. Chandra AB, Chandra PA, Chapnick EK. Bacteremia caused by *Brevundimonas vesicularis* in a patient with biliary pancreatitis. *Infec Dis Clin Pract* 2010; 18: 54-5.
6. Chi CY, Fung CP, Wong WW, Liu CY. *Brevundimonas* bacteremia: two case reports and literature review. *Scand J Infect Dis* 2004; 36: 59-77.
7. Gilad J, Borer A, Peled N et al. Hospital-acquired *Brevundimonas vesicularis* septicaemia following open-heart surgery: case report and literature review. *Scand J Infect Dis* 2000; 32: 90-1.
8. Oberheiman RA, Lambert JR, Santorelli FW. *Pseudomonas vesicularis* causing bacteremia in a child with sickle cell anemia. *South Med J* 1994; 87: 821-2.
9. Karadag N, Karagol BS, Kundak AA et al. Spectrum of *Brevundimonas vesicularis* infections in neonatal period: a case series at a tertiary referral center. *Infection* 2012; 40: 509-15.
10. Radostits OM, Gay CC, Hinchcliff KW, Constable PD, eds. *Veterinary medicine: a textbook of the diseases of cattle, horses, sheep, pigs and goats*. 10th ed. Philadelphia: WB Saunders, 2007: 127-31.
11. Capen CC. The endocrine glands. In: Jubb KVF, Kennedy PC, Palmer N, eds. *Pathology of domestic animals*. 4th ed. Vol. 3. San Diego: Academic Press, 1993: 315-6.
12. Bries J, Bratko P, Weissova T, Michna A,

Matisák T. Iodine deficiency in goats as a cause of congenital goiter in kids. *Vet Med (Praha)* 1996; 41:133–8.

13. Matthews JG. *Diseases of the goat*. Oxford: Blackwell Science, 1999: 56–7.

14. De Vito P, Incerpi S, Pedersen JZ, et al. Thyroid hormones as modulators of immune activities at the cellular level. *Thyroid* 2011; 21(8): e879–90. <http://online.liebertpub.com/doi/abs/10.1089/thy.2010.0429> (12. 9. 2016)

15. Pelletier JS, Ide T, Yoo SH. *Brevundimonas vesicularis* keratitis after laser in situ keratomileusis. *J Cataract Refract Surg* 2010; 36: 340–3.

16. Gupta PK, Appannanavar SB, Kaur H, Gupta V, Mohan B, Taneja N. Hospital acquired urinary tract infection by multidrug-resistant *Bre-*

*vundimonas vesicularis*. *Indian J Pathol Microbiol* 2014; 57: 486–8. <http://www.ijpmonline.org/article.asp?issn=0377-4929;year=2014;volume=57;issue=3;spage=486;epage=488;aulast=Gupta>

17. Yoo SH, Kim MJ, Roh KH, et al. Liver abscess caused by *Brevundimonas vesicularis* in an immunocompetent patient. *J Med Microbiol* 2012; 61: 1476–9. <http://jmm.sgmjournals.org/content/journal/jmm/10.1099/jmm.0.045120-0?crawler=true&mimetype=application/pdf>

18. Karadag N, Karagol BS, Dursun A, Okumus N, Tanir G, Zenciroglu A. A premature neonate with early-onset neonatal sepsis owing to *Brevundimonas vesicularis* complicated by persistent meningitis and lymphadenopathy. *Paediatr Int Child Health* 2012; 32: 239–41.

## ***Brevundimonas vesicularis* SEPSA PRI KOZLIČKU S PRIROJENO GOLŠAVOSTJO**

M. Gombač, I. Gruntar, P. Kvpil, T. Švara

**Povzetek:** V prispevku smo opisali sepso, ki jo je pri novorojenem pritlikavem kozličku z golšavostjo povzročila bakterija *Brevundimonas vesicularis*. *B. vesicularis* je aerobna, nesporogena, gibljiva, gramsko negativna ubikvitarna bakterija, ki je občutljiva na aminoglikozide in nekatere peniciline. Do sedaj so jo izolirali iz vode, zemlje, rastlin in ljudi, predvsem imunosupresivnih bolnikov, pri katerih je povzročila endokarditis, artritis, keratitis in sepso. V literaturi ni zabeleženo, da bi ta bakterija pri živalih povzročila katere koli bolezenske spremembe.

Pritlikavi kozliček je poginil 18 ur po normalnem porodu. Pred poginom ni kazal bolezenskih znakov, bil je normalno razvit in v dobri telesni kondiciji, normalno je sesal. Med raztelesbo smo ugotovili obojestransko močno povečano ščitnico, akutno embolično pljučnico, akutni kataralni enteritis in zmerno splenomegalijo. Spatohistološko preiskavo smo potrdili močno hiperplazijo ščitnice, embolično pljučnico in kataralni enteritis, v jetrih in miokardu smo opazili majhne multifokalne nekroze, obdane s posameznimi nevtrofilci, vranica je bila močno hiperplastična, v ledvicah pa smo ugotovili močno parenhimsko degeneracijo tubulocitov. V pljučih in jetrih smo opazili številne majhne kolonije gramsko negativnih bakterij. Na krvnem agarju so iz pljuč, jeter in vranice v čisti kulturi zrastle gladke, debele, izbočene, rumenkaste bakterijske kolonije, na agarju po Drigalskem pa zelene bakterijske kolonije. Izolirane bakterije smo determinirali kot *B. vesicularis*. Bakterije so bile občutljive na širok spekter antibiotikov, vključujoč ampicilin, cefotaksim, ceftriakson in ceftazidim-klavulanat.

Predstavljeni primer je prvi opis z *B. vesicularis* povzročene sepse pri živali. Imunosupresivni kozlički so zaradi golšavosti dovzetnejši za številne bakterijske okužbe, med katere gotovo lahko prištevamo tudi okužbo z *B. vesicularis*, ki lahko povzroči sepso in pogin v nekaj urah.

**Ključne besede:** *Brevundimonas vesicularis*; kongenitalna golšavost; novorojeni kozlički; pljučnica; sepsa